



## Repair of fractures in the bone of caudal fin for *Xiphophorus helleri* fish under the influence of hydrocortisone hormone

Ali A.A. Al-Ali\*, Muneerah A. Ibrahim

*Department of Biology, College of Education for Pure Science, University of Basrah, Iraq*

**Key words:** *X. helleri*, Caudal fin, Hydrocortisone hormone, Fractions repairing.

<http://dx.doi.org/10.12692/ijb/15.4.115-126>

Article published on October 08, 2019

### Abstract

The manufactured Glucocorticoid hormones (GC) are regarded as one of the most important drugs which used in treatment of many pathological conditions. The use of (GC) causes risk increasing of fractures at all age levels, as it affects the process of repairing fractures. The current experiment was designed by using male fish *Xiphophorus helleri* (24 male) which were divided in to two groups. The first group was a control group while the second group was treated. The second group were treated with Hydrocortisone with 2.5 mg/l concentration. After 8 days of treatment, the fractures were done in the caudal fins of both groups. This was done with anatomical microscope by a blade in different places of fin rays of caudal fin. Samples were saved for both groups by formalin stabilizer concentration 10% at different time intervals (0, 2, 5, and 14) day, starting at zero hour by three replicates for each stage. The samples were examined by a SEM and tissues pieces was prepared by using paraffin waxes. The results showed after two days a repair occurs to the soft tissue around the fracture position in both group. As the days progressed, the amount of osteoid increased which caused fracture area fusion, while treated group samples were still free of any bony material till the last day of the experiment. The present study suggested the Hydrocortisone hormone has a positive effect on repairing the soft tissues and negative effects on repairing hard tissues.

\*Corresponding Author: Al-Ali ✉ [qalialali\\_75@Ymail.Com](mailto:qalialali_75@Ymail.Com)

## Introduction

Many drugs and medicines that used in treatment of various pathological conditions effect on the formation of bone and its remodeling. Manufactured Glucocorticoid hormones (GC) are regarded as one of the most important of these drugs. GC hormones are widely used in the treatment of many Human clinical conditions such as, autoimmune, rheumatologic, gastrointestinal diseases, malignancies and organs transplantation. Through the wide range use of these hormones it has been found that they have a detrimental effect on various body systems including the skeleton (Van Staa *et al.*, 2000; Mc-Donough *et al.*, 2008).

GC hormones induces Secondary Osteoporosis. Using GC hormones is considered as an indication to increase the risk of fractures at all the age stages (Kaniset *al.*, 2004). It has been found that the patients who were using these hormones as a chronic or prolonged treatment more than three months, are exposed to bone fractures more than 50% (Bouvardetal., 2010).The risk of bone fractures begins soon after the beginning of glucocorticoid hormone therapy, even at used low therapeutic dose, it be amenable to induce fractures (Van Staa *et al.*, 2000).

Some studies have indicated to the effect of GC on the process of repairing fractures, mineral content in the bone also reduce the rate Fibroblasts even they reduce accumulation of the formed collagen during the process of repairing the fractures. In addition to their role in slowing the process of Endochondral Ossification (Waters *et al.*, 2000; Sawin *et al.*, 2001).

The effect of GC hormones depends on the size or quantity of the dose and the duration of the dose that used in, in the process of repairing fractures. As the single short- term dose has no effect on the bone repairing process, while it be delayed in long- term dose (Hogevold *et al.*, 1992; Aslan *et al.*, 2005).

In spite of previous studies information about the effect of (GC) hormones on the repairing fractures process on the one hand and the effect of the dose

amount and the treatment period on the other hand. Information about this process is still unclear. So in order to add academic information about fractures repairing under the influence of (GC) hormones and to complete the previous studies. The current study aimed to study the effect of hydrocortisone hormone on fractures repairing in caudal fin of *X. helleri* fish.

## Materials and methods

The experiment was designed by using (24 fish) *X. helleri* fish which divided to two groups, one counted as the control group while the second group as treated one. Fish of both two groups were placed in glass ponds 60 liters capacity which were supplied with feeding and continuous ventilation devices. Fish were left acclimate in the lab, after one week, the second group fish were treated with hydrocortisone hormone sodium succinate Netherlands (Roxcortisone), for 22 days with 2.5 mg/l concentration. (Mazloum *et al.*, 2015. As the hormone was dissolved in the water of ponds where fish are located.

Fish were anaesthetized using clove oil solution (150ppm) and killed by spinal section. Fractures were done in the caudal fin of both groups (the control and treated, after 8 days of treatment with Hydrocortisone hormone under the Anatomical Microscope by using the blade. Those fractures were done in different places in rays Lepidotrichia of the caudal fin (Fig. 1).

The samples of both two groups (control and treated) are fixed by using the stabilizer formalin with 10% concentration on different duration (0,2,5&14) day, begins at zero hour of the experiment (the moment of making the fracture) with three replicates for each stage.

### *Ethical approval*

Ethical approval to deal with animal specimens before preparation of tissue sections was approved by the ethics committee at the University of Basrah.

### *Examination of samples*

*Examination of samples by light microscope*

After fixing the samples of both two groups( control and treated) by 10% formalin, the last quarter was cut off from the fish body including the caudal fin, then it was placed on glass slides, where fracture sites were examined and photographed which were induced in the caudal fin by Leica photographic microscope.

#### *Examination of samples by Scanning Electronic Microscope (SEM)*

In order to examine the samples by (SEM) the caudal fin had been placed on glass slides for both two groups (control and treated) to dry it by using hot plate, after that the samples were completely dried, the samples were inserted into a special device which is used to paint with gold material, in order to be configured for examination by (SEM) (Bancroft and Gamble, 2008), then the samples were transferred to the (SEM) for taking its photo.

#### *Preparation of tissue sections*


The ordinary tissue sections for caudal fins *X.helleri* fish was prepared for both two groups (control and treated) depending on Humason (1972) method, before waxing with paraffin, the samples were washed with tap water for 12 hours to remove the stabilizer then preserved with ethyl alcohol 70% concentration .Then the dehydration process was performed by passing the samples with upward concentrations of ethyl alcohol 80% and 90% for an hour each with changing and 100% concentration for 5 hours with changing each hour. The samples were then clearing with xylene for 10 minutes then transferred to molten paraffin wax in electric oven of 60°C temperature for five hours, the purpose was to infiltration the samples with wax with changing each hour.

Then, the samples were embedded with pure wax by using suitable copper molds. After infiltration the wax molds which the samples in. They had been cut at a thickness of 7 micrometers with rotary microtome. Then, the sections tapes were transferred to 40-45°C water bath to allow stretching and flattening the tapes, they were loaded on clean glass slides, then the sections were dyed in a double stain hematoxylin and eosin. After that the sections were examined and

photographed by leica microscope.

#### **Results**

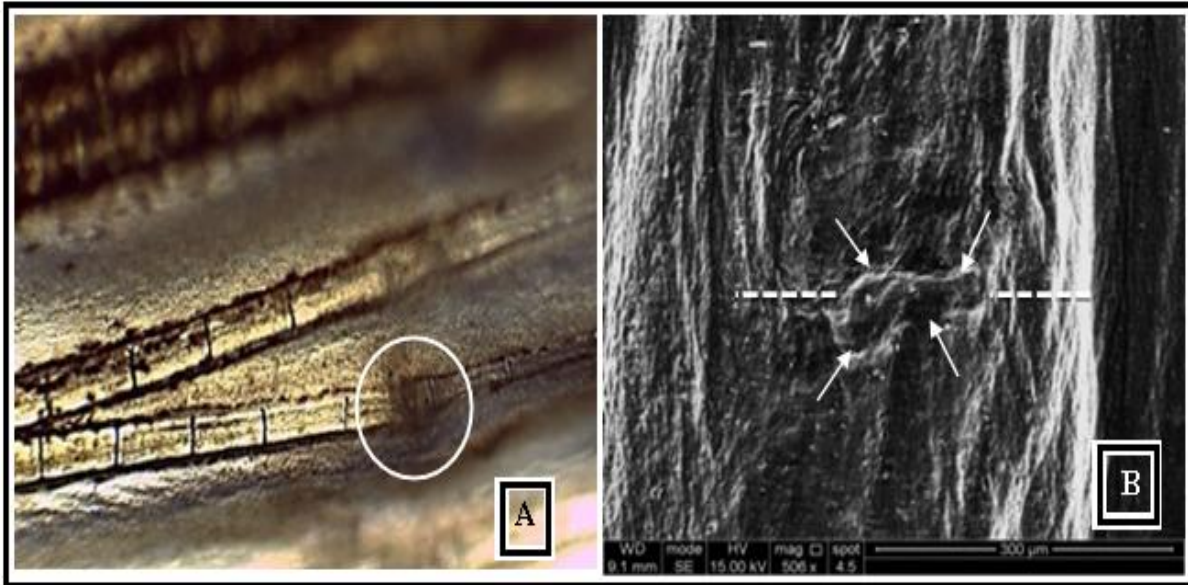
After following up the fractures, the results of phenotypic examination, (SEM) and Histological sections of the caudal fin bones of the *X. helleri* fish, showed that there is an effect to hydrocortisone on the fractures repairing process in the treated group in comparison to control group.



**Fig. 1.** (A). Fracture in the different areas of caudal fin of *X. helleri* males by using blade. The yellow lines represent positions of fractures in the fin, the arrow refers to the extended sword from the caudal fin of male. (B)The blade is used for making fracture.(C) The fracture is made(arrows) in the caudal fin rays of *X. helleri* fish in zero hour of the experiment. The 40x mag.

#### *After two days of fraction*

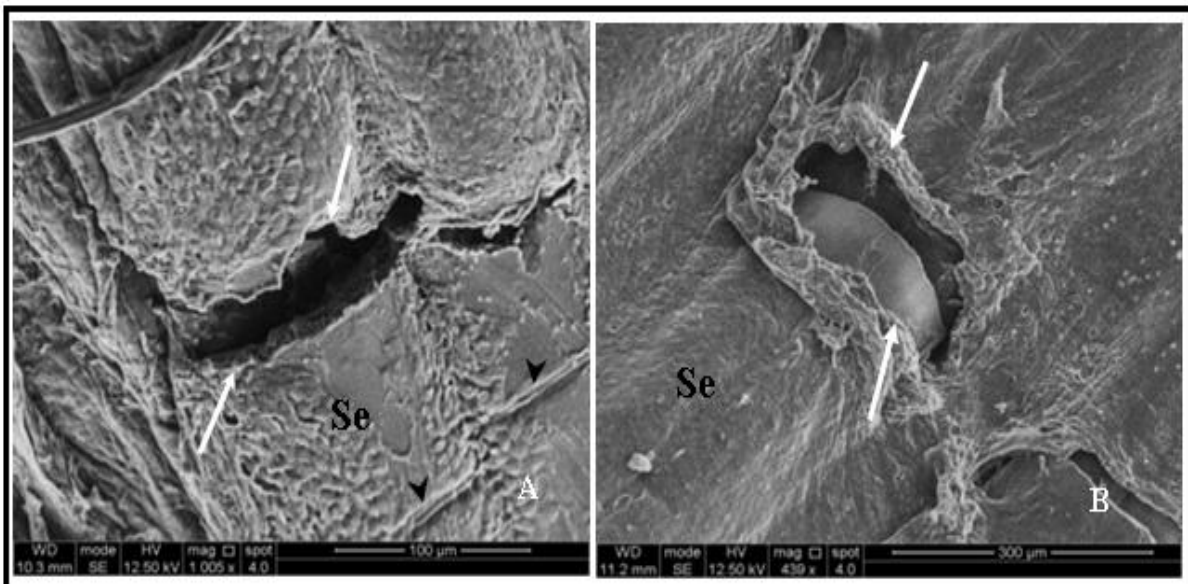
The result examination of the fraction area, showed in the control group samples under Anatomical Microscope and (SEM) that there was a build and repair in the fracture area (Fig.2).



**Fig. 2.** The fracture in the caudal fin ray bone of *X. helleri* of control group after two days of fracture,(A)The fracture(circle) 40x mag.(B)Explain what has been left the torn tissues (arrows) notice the region of construction of tissue(the inter mitten line) SEM, 506X mag.

As the torn tissues appeared in the fracture area it occupies a small area compared to that area it was filled in zero time of fracture (Fig.1C & 3A), while the entire structure of the torn tissue appeared full construction a round bone in the fracture area in the

treated group samples compared with control group at zero time of making the fracture of treatment group. The fracture area in the treated group samples appears puffy more than it is in the control group (Fig. 3B & 4).




**Fig. 3.** Fracture (arrows) is made in bone of caudal fin rays of *X. helleri* fishin zero hour of experiment,(head arrow) explain a Joni, Segment (Se). (A) Control group, SEM, 1005X. (B) treated group, SEM, 439X.

The study of longitudinal tissue section in fin rays of control and treated groups samples indicated that a thin collagen fibrous tissue is formed, filling the

fracture area and what is around. Its quantity in the treated group was more than it is in control group (Fig. 5B). In return, osteoid interlayer that accepts

eosin stain in the light pink color is appeared in the fracture area of the control group samples. Tissue sections showed that a repair has occurred to the epithelial tissue portion which appeared in the section

of both two groups. The segment cavity was filled with connective tissue, it was clearer in treated group more than control group (Fig.5A).

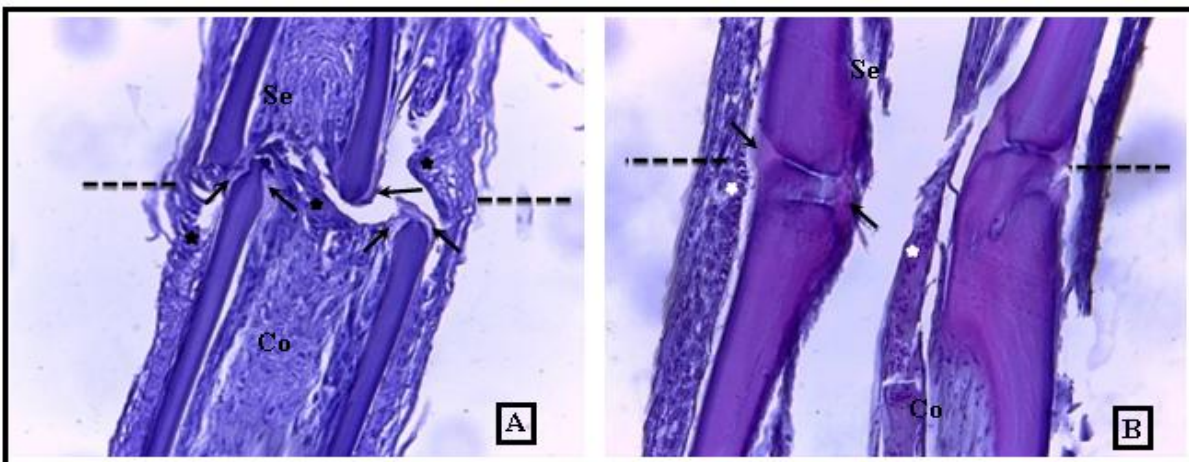


**Fig. 4.** Fracture in the bones of caudle fin rays' bone of *X.helleri* fish of treated group after two days of fracture. (A) The circle explains the fracture region, 40x mag. (B) Show the swollen in the fracture region (intermittent line) 462X mag.

*After 5 days of fraction*

With the progress of experiment days, in the fifth day, the soft tissue in the fracture area, seemed completely repaired, in the sample which examined in Electronic Microscope of the control group. It seemed also that

the fracture had been repaired (Fig.6A).The tissue sections of the fracture area showed a fusion occurred to the fin rays bone as a result of increasing in the bony material in this area.

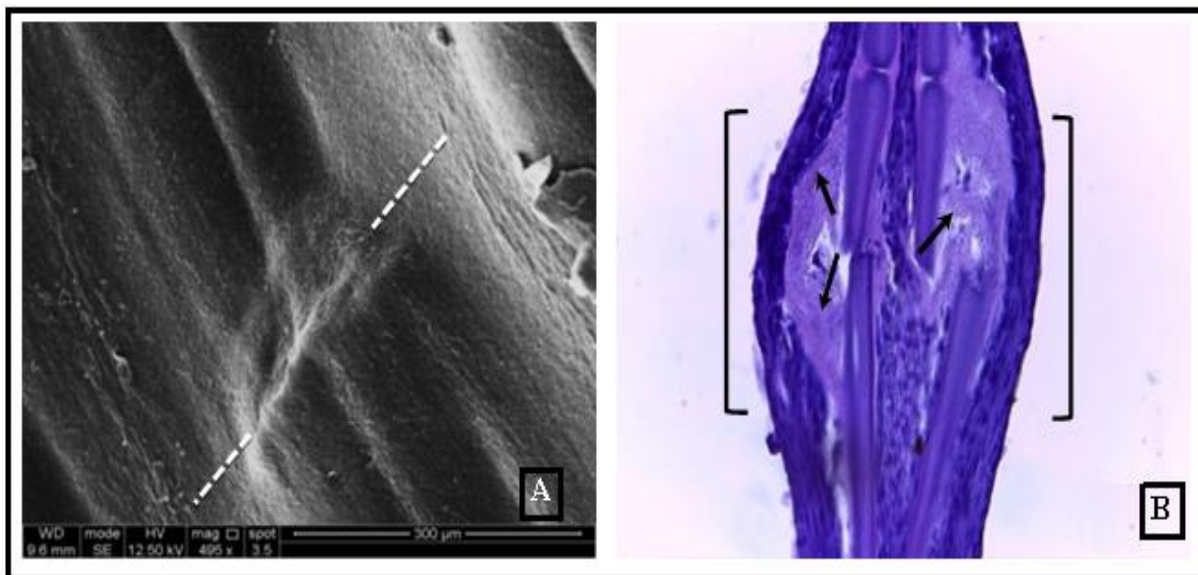


**Fig. 5.** Lateral longitudinal tissue section in fracture area (intermittent line) in the bone of caudle fin rays of *X. helleri* fish after two days of fraction, H&E,400X mag. (A)Treated group,notice the configuration of collagen fibrous tissue (stars) between and around the fraction and the increasing in connective tissue breeding (Co) segment cavity and formation of callus tissue in the fracture area(arrows), segment (Se). (B)Control group, notice the osteoid interstitial material in fracture area (arrows) and collagen fibrous tissue (stars), Segment (Se), connective tissue (Co).

The two ends of the fractured bone appeared connected together by interstitial bone material filled the fracture area which led to appear as swollen (Fig.6B).

As for treated group, the superficial soft tissue in the fracture area fully repaired (Fig.7A). The studies of

tissues sections for the treated group samples showed that there is no difference in the fracture area of what they were in the previous period (after two days of fracture) except the continuity of connective tissue reproduction in the fracture area. The tissues sections didn't appear bony material formation comparing with the control group (Fig.7B).



**Fig. 6.** Fracture area in the bone rays of caudle fin of *X. helleri* fish of control group after five days of fraction.(A) Notice the complete repairing of soft tissue and also reformation of fraction (intermittent line) in fracture area, SEM,495X mag. (B) Lateral longitudinal section in fracture area (brackets), notice the continuity of formation of osteoid material in the fracture area (arrows),H&E,400X mag.

#### After 14 days of fraction


The results of microscopic examination of control group samples showed fully fusion to the fracture area and showed it was closer to the natural form (Fig.8A). The examination results of the tissue sections have indicated fusion of two sides of bone by thick bone material with a clear decrease in the amount of the connective tissue in the ray's cavity (Fig.8B). While fin rays of treated group showed deformation in the fracture area (Fig.9A). The tissue sections showed during this period of the experiment no formation of bone material in the fracture area and only connective tissue still fills the area (Fig.9B).

#### Discussion

As in other vertebrates, bony fish have the ability to repair bone fractures through a series of vital processes, starting with external soft damage tissues

repairing, as the epidermis layer down to repair hard tissue, bone, the process of forming Epidermis and connective tissue layers or Epidermis during fracture repair, the first step of repairing process and the fastest and the most important to success this process.

The Epithelial tissue layers that formed in fracture area are working to cover injuries. Thus they avoid the external infections which cause infections (Iee *et al.*, 2009). This is evidenced by the results of the current study, as the repairing process and construction of soft tissue which surrounding the fracture area, appeared clearly after two days of fracture in caudle fin bone in both treated and control groups. However, the repairing process of the torn tissues in the fracture area of treated group was faster comparing to control group.



**Fig. 7.** Fracture area in the bone rays of caudal fin of *X. helleri* fish of treated group after 5 days of fraction. (A) Notice the complete repairing of soft tissue around the fracture area (intermittent line) in fracture area. SEM, 997X mag. (B) Lateral longitudinal section in the fracture area (brackets), notice deformation of bony material in the fracture area (stars) and the fracture staying infusion and increasing of connective tissue breeding around fracture area (arrows), H&E, 400X mag.

The reason was the ability of GC hormone to induce increasing the speed of reproduction the soft cells, like epithelial tissue (Bouncier *et al.*, 2000). Which led to increasing in speed of repairing process of those tissues comparing to control group.

Studies differed about the effect of manufactured GC hormone when it used in short and long-term treatment on the repairing fractures process. Some studies had shown there is on confirmed indicators prove inhibition of reformation of bone at treatment with short-term GC hormones (Aslan *et al.*, 2005; Li *et al.*, 2012). While another study found that long-term treatment with GC hormones weaken and inhibited bone reconfiguration process (Water *et al.*, 2000; Liu *et al.*, 2018).

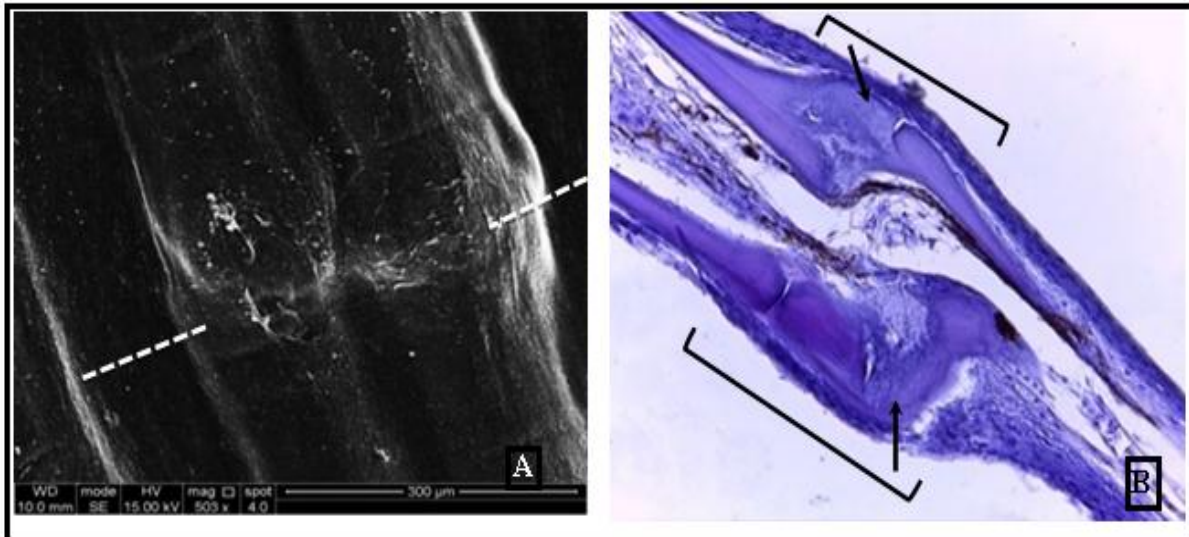
These studies have agreed with the present study results which showed presence of clear inhibitor effect on the repairing process that was occurred in the caudal fin rays of *X. helleri* fish. Which was treated with hydrocortisone hormone for 22 days this period is regarded as long-term treatment period. It was found that the fractures were occurred in the caudal fin rays of the treated group didn't have any repairing

process, comparing with control group which showed that bones were completely repaired in the fourteenth day of the experiment.

Both the immune system and skeletal cells involve in fractures repairing process. The fracture area attracts macrophages, Mast cells, Mesenchyme cells and endothelial cells, this stage called inflammatory phase, which removes the damage tissues and builds new blood vessels.

After inflammatory phase ends the Regenerative phase starts which in it the Granulation tissue or soft callus formation occurs, this represents the first stage of Regenerative phase of repairing fractures process, which contains Mesenchyme progenitor cells, in turn it differentiate into the osteoblast lineage, to repair the fracture (Hachemi *et al.*, 2018).

The examination results of the tissue sections showed that the quantity of Granulation tissue in fracture area and what around it in the caudal fin rays bone of *X. helleri* of the treated group samples were bigger than it was in control group samples.



**Fig. 8.** Fracture area of bone rays of caudle fin of *X. helleri* fish of control group after 14 days of fracture. (A) Complete fusion of fracture (intermittent line), SEM,503X mag. (B) Lateral longitudinal section of fracture area (brackets), notice fracture fusion completely by thick bony material (arrows) , H&E,400X mag.

That reflexes the role of hydrocortisone hormone which speeds breeding of soft tissues cells comparing with the normal state. This explains the appearance of clear bulge in the fracture area in the treated group comparing with control group.

In the tissue sections samples of control group have been noticed that Granulation tissue are replaced by osteoid material after two days of fraction. It represented by bony callus. After 14 day of fraction the quantity of this material increased, as a result of that the two ends of the fracture bone are connected and appeared united like its normal shape, while the fracture area of treated group samples still in soft callus till the end of the experiment.

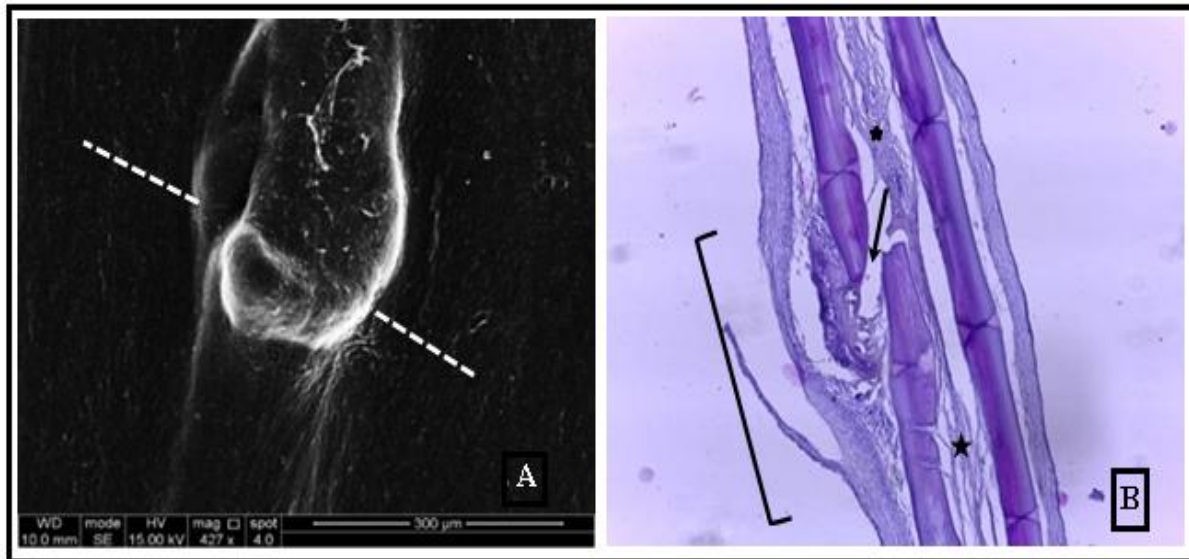
The reason behind that was the effect of GC hormones on the hard and soft tissues which are working to increase the soft tissues cells breeding. Which GC hormones frustrate the configuration and breeding of the hard tissues like bony tissue (Alsaimey, 2018). Which led to not configure the osteoid material in the fracture area of the treated group (Mathew *et al.*, 2007; Oppedal and Goldsmith, 2010; Sandberg and Aspenbery, 2015). Frustration of reconfigure bone is regarded as one of the main qualities of GC hormones in mammalia (Canalis and Delany, 2002), the GC hormones lead to induce programmed death

to the mature cells which build bone thus they decreased their number (Canalis *et al.*, 2007; Weinstein, 2011).

In addition to decrease differentiation of osteoprogenitor in bone marrow to osteoblast. GC hormones play role to curb the osteoblast job and its effectiveness (Liu *et al.*, 2015; Liu *et al.*, 2016). Those hormones inhibited building collagen in addition, they hydrolyzed collagen in two types I and III (Oishi *et al.*, 2002).

This illustrates the reasons behind lateness of semi-bone material configuration in treated group samples, this confirms what Bechara *et al.* (2000) had found out, that is Dexamethasone hormone leads to weaken collagen configuration in fins of bony fish. The GC hormones affect osteoclast too they increase gene expression of gene RANKL (Rubln *et al.*, 1998; Dovic *et al.*, 2006; Liu *et al.*, 2016) that works in turn to increase number and effectiveness of bone osteoclasts thus increasing in bone resorption in other cases, it has been found that GC hormones have direct effect to prevent changes in cell structure of osteoclasts which are important to increase its ability of boneresorption also to prevent proliferation of cells lineage of the osteoclast (Weinstein *et al.*, 1998; Kim *et al.*, 2006; Kim *et al.*, 2007).





**Fig. 9.** Fracture area (intermittent line) in the bone rays of caudal fin of *X.helleri* fish of treated group after 14 days of fraction. (A) Explains deformation in the fracture area, SEM,213X mag. (B) Lateral longitudinal section in the fracture area(bracket), notice infusion fracture(arrows) and connective tissue which still filling the segment cavity (two stars), H&E, 400X mag.

This may be gives another reason why do not repair fractions in caudal fin bones of fish which were treated with hydrocortisone hormone comparing with control group as a result of the effect of that hormone on osteoblast and osteoclast cells. Through examining with the scanner electronic microscope to the fracture area, was noticed that the treated group samples in the 14<sup>th</sup> day of making fracture, there was clear deformation in that area comparing with natural repairing in the fracture area of control group. This confirms the role of GC hormones and their negative effect on the repairing fracture process (Tolar *et al.*, 2004).

### Conclusion

The *X.helleri* fish gave an approximate integrated image about the stages of repairing fractures in a short time comparing with other animals which makes it as a good modal to study fracture repairing process. Hydrocortisone hormone has a positive effect on repairing the soft tissues and negative effects on repairing hard tissues in *X.helleri* fish fins.

### References

**Al-saimary AS.** 2018. Effect of hydrocortisone hormone on the bone tissue differentiation and

some histological and physiological changes in female's mice *Mus musculus* L. P.H.D. thesis, Basra University/ Collage of Education for Pure Science, p 217.

**Aslan M, Simsek G, Yildirim U.** 2005. Effect of short-term treatment with systemic prednisone on bone healing: an experimental study in rats. *Dental Traumatology* **21**,222-225.

<http://dx.doi.org/10.1111/j.1600-9657.2005.00300.x>

**Bancroft JD, Gamble M.** 2008. Theory and Practice of Histological Techniques. 6<sup>th</sup> ed. Churchill Livingstone 692p.

**Bechara IJ, Joazeiro PP, Marí-Beffa M, Becerra J, Montes GS.** 2000. Collagen-affecting drugs impair regeneration of teleost tail fins. *Journal of Submicroscopic Cytology and Pathology* **32(2)**, 273-280.

**Bourcier T, Forgez P, Borderie V, Scheer S, Rostène W, Laroche L.** 2002. Regulation of human corneal epithelial cell proliferation and apoptosis by Dexamethasone. *Investigative Ophthalmology & Visual Science* **41(13)**, 4133-4141.

- Bouvard B, Legrand E, Audran M, Chappard D.** 2010. Glucocorticoid-Induced Osteoporosis: A Review. *Clinical Reviews in Bone and Mineral Metabolism* **8**, 15-26.  
<http://dx.doi.org/10.1007/s12018-009-9051-9>
- Canalis E, Delany AM.** 2002. Mechanisms of glucocorticoid action in bone. *Annals of the New York Academy of Sciences* **966**, 73-81.  
<http://dx.doi.org/10.1111/j.17496632.2002.tb04204.x>
- Canalis E, Mazziotti G, Giustina A, Bilezikian JP.** 2007. Glucocorticoid-induced osteoporosis: pathophysiology and therapy. *Osteoporosis International* **18(10)**, 1319-1328.  
<http://dx.doi.org/10.1007/s00198-007-0394-0>
- Dovio A, Perazzolo L, Saba L, Termine A, Capobianco M, Bertolotto A, Angeli A.** 2006. High-dose glucocorticoids increase serum levels of soluble IL-6 receptor alpha and its ratio to soluble gp130: an additional mechanism for early increased bone resorption. *European Journal Endocrinology* **154(5)**, 745-751.  
<https://doi.org/10.1530/eje.1.02147>
- Hachemi Y, Rapp A E, Picke A K, Weidinger G, Ignatius A, Tuckermann J.** 2018. Molecular mechanisms of glucocorticoids on skeleton and bone regeneration after fracture. *Journal of Molecular Endocrinology* **61**, 75-90.  
<http://dx.doi.org/10.1530/JME-18-0024>
- Høgevoid HE, Grøgaard B, Reikerås O.** 1992. Effects of short- term treatment with corticosteroids and indomethacin on bone healing. A mechanical study of osteotomies in rats. *Acta Orthopaedica Scandinavica* **63(6)**, 607-611.  
<http://dx.doi.org/10.1080/17453679209169718>
- Humason GL.** 1972. *Animal tissue techniques*. 3<sup>rd</sup> ed. W. h. Freeman and Company, son fran- 614 p.
- Kanis JA, Johansson H, Oden A, Johnell O, de Laet C, Melton III LJ, Tenenhouse A, Reeve J, Silman AJ, Pols HA, Eisman JA, McCloskey EV, Mellstrom D.** 2004. A meta-analysis of prior corticosteroid use and fracture risk. *Journal of Bone and Mineral Reviews* **19**, 893-899.  
<http://dx.doi.org/10.1359/JBMR.040134>.
- Kim HJ, Zhao H, Kitaura H, Bhattacharyya S, Brewer JA, Muglia LJ, Ross FP, Teitelbaum SL.** 2006. Glucocorticoids suppress bone formation via the osteoclast. *Journal of Clinical. Investigation* **116(8)**, 2152-2160.  
<http://dx.doi.org/10.1172/JCI28084>.
- Kim HJ, Zhao H, Kitaura H, Bhattacharyya S, Brewer JA, Muglia LJ, Ross FP, Teitelbaum SL.** 2007. Glucocorticoids and the osteoclast. *Annals of the New York Academy of Sciences* **1116**, 335-339.  
<http://dx.doi.org/10.1196/annals.1402.057>
- Lee Y, Hami D, De Val S, Kagermeier-Schenk B, Wills AA, Black BL, Weidinger G, Poss KD.** 2009. Maintenance of blastemal proliferation by functionally diverse epidermis in regenerating zebrafish fins. *Developmental Biology* **331**, 270-280.  
<http://dx.doi.org/10.1016/j.ydbio.2009.05.545>
- Li J, Wang X, Zhou C, Liu L, Wu Y, Wang D, Jiang H.** 2012. Perioperative glucocorticosteroid treatment delays early healing of a mandible wound by inhibiting osteogenic differentiation. *Injury* **43**, 12841289.  
<https://doi.org/10.1016/j.injury.2012.04.014>
- Liu Y, Akhter MP, Gao X, Wang Xiao-yan, Wang Xiao-bei Zhao G, Wei X, Wu H, Chen H, Wang D, Cui L.** 2018. Glucocorticoid- induced delayed fracture healing and impaired bone biomechanical properties in mice. *Clinical Interventions in Aging* **13**, 1465-1474.  
<https://doi.org/10.2147/CIA.S167431>
- Liu Y, Cui Y, Chen Y, Gao X, Su Y, Cui L.** 2015. Effects of dexamethasone, celecoxib and methotrexate on the histology and metabolism of

bone tissue in healthy Sprague Dawley rats. *Clinical Interventions in Aging* **10**, 1245-1253.

<https://doi.org/10.2147/CIA.S85225>

**Liu Y, Cui Y, Zhang X, Gao X, Su Y, Xu B, Wu T, Chen W, Cui L.** 2016. Effects of salvianolate on bone metabolism in glucocorticoid-treated lupus-prone B6.MRL-Fas(lpr)/J mice. *Drug Design Development and Therapy* **10**, 2535-2546.

<http://dx.doi.org/10.2147/DDDT.S110125>

**Mathew LK, Sengupta S, Kawakami A, Andreasen EA, Lohr CV, Loynes CA, Renshaw SA, Peterson RT, Tanguay RL.** 2007. Unraveling tissue regeneration pathways using chemical genetics. *Journal of Biological Chemistry* **282**, 35202-35210.

<http://dx.doi.org/10.1074/jbc.M706640200>

**Mazloumi N, Amiri BM, Nematollahi M, Rafeem G.** 2015. Hydrocortisone treatment may enhance survival and stocking of Beluga sturgeon (*Huso huso* Linnaeus, 1758) in estuaries of the Caspian Sea. *International Journal of Aquatic Biology* **3(3)**, 129-134.

**McDonough AK, Curtis JR, Saag KG.** 2008. The epidemiology of glucocorticoid-associated adverse events. *Current Opinion in Rheumatology* **20**, 131-137.

<http://dx.doi.org/10.1097/BOR.0b013e3282f51031>

**Oishi Y, Fu ZW, Ohnuki Y, Kato H, Noguchi T.** 2002. Molecular basis of the alteration in skin collagen metabolism in response to in vivo dexamethasone treatment: effects on the synthesis of collagen type I and III, collagenase, and tissue inhibitors of metalloproteinases. *The British Journal of Dermatology* **147(5)**, 859-868.

<http://dx.doi.org/10.1046/j.1365-2133.2002.04949.x>

**Oppedal D, Goldsmith MI.** 2010. A chemical screen to identify novel inhibitors of fin regeneration in zebrafish. *Zebrafish* **7**, 53-60.

<http://dx.doi.org/10.1089/zeb.2009.0633>

**Rubin J, Biskobing DM, Jadhav L, Fan D, Nanes MS, Perkins S, Fan X.** 1998. Dexamethasone promotes expression of membrane-bound macrophage colony-stimulating factor in murine osteoblast-like cells. *Endocrinology* **139(3)**, 1006-1012.

<https://doi.org/10.1210/endo.139.3.5778>

**Sandberg OH, Aspenberg P.** 2015. Glucocorticoids inhibit shaft fracture healing but not metaphyseal bone regeneration under stable mechanical conditions. *Bone and Joint Research* **4**, 170-175.

<http://dx.doi.org/10.1302/2046-3758.410.2000414>

**Sawin PD, Dickman CA, Crawford NR, Melton MS, Bichard WD, Sonntag VK.** 2001. The effects of dexamethasone on bone fusion in an experimental model of posterolateral lumbar spinal arthrodesis. *Journal of Neurosurgery* **94(1Suppl)**, 76-81.

<http://dx.doi.org/10.3171/spi.2001.94.1.0076>

**Tolar J, Teitelbaum SL, Orchard PJ.** 2004. Osteopetrosis. *The New England Journal of Medicine* **351**, 2839-2849.

**Van Staa TP, Leufkens HG, Abenhaim L, Begaud B, Zhang B, Cooper C.** 2000. Use of oral corticosteroids in the United Kingdom. *Monthly Journal of The Association of physicians* **93**, 105-111.

<http://dx.doi.org/10.1093/qjmed/93.2.105>

**Waters RV, Gamradt SC, Asnis P, Vickery BH, Avnur Z, Hill E, Bostrom M.** 2000. Systemic corticosteroids inhibit bone healing in a rabbit ulnar osteotomy model. *Acta Orthopaedica Scandinavica* **71(3)**, 316-321.

<http://dx.doi.org/10.1080/000164700317411951>

**Weinstein RS.** 2011. Clinical practice. Glucocorticoid-induced bone disease. *The New England Journal of Medicine* **365(1)**, 62-70.

<http://dx.doi.org/10.1056/NEJMcp1012926>

**Weinstein RS, Jilka RL, Parfitt AM,**

**Manolagas SC.** 1998. Inhibition of osteoblast genesis and promotion of apoptosis of osteoblasts and osteocytes by glucocorticoids. Potential mechanisms

of their deleterious effects on bone. The Journal of Clinical Investigation **102(2)**, 274-282.  
<http://dx.doi.org/10.1172/JCI2799>