



RESEARCH PAPER

OPEN ACCESS

Implications of prophetic factors and their potential role in the development of radicular cyst

Arif Malik^{*1}, Ayesha Zahid¹, Shahzad Ahmad², Sulayman Waquar¹,
Muhammad Abdul Basit Ashraf¹

¹*Institute of Molecular Biology and Biotechnology (IMBB), The University of Lahore, Pakistan*

²*FMH College of Medicine and Dentistry, Lahore, Pakistan*

Key words: LPS (Lipopolysaccharides), iNOS (Inducible nitric Oxide synthase), NO (Nitric Oxide), SOD (Superoxide dismutase), Radicular cyst (RC), Advanced oxidation protein products (AOPPs), Matrix metalloproteinases (MMPs)

<http://dx.doi.org/10.12692/ijb/10.2.201-209>

Article published on February 28, 2017

Abstract

Radicular cyst (RC) is the most common endodontic and inflammatory disease encompasses damage of periradicular tissues and resorption of bone adjacent to root of exaggerated teeth. Inflammatory cytokines uphold cyst growth and bone resorption as they are responsible to modulate bone remodeling. Reactive oxygen species (ROS) and nitric oxide derived from macrophages after bacterial lipopolysaccharides (LPS) may enhance bone loss by boosting the cytokine induced matrix metalloproteinases (MMPs) production in osteoblasts. Forty samples of radicular cysts and twenty from normal pulp were taken from extracted teeth (As control). Glutathione (GSH), Glutathione reductase (GRx), Glutathione peroxidase (GPx), Catalase (CAT), Malondialdehyde (MDA), superoxide dismutase (SOD), Vitamin-C, Vitamin-E, Nitric oxide (NO), Lipopolysaccharides (LPS), advanced oxidation protein products (AOPPs), advanced glycation end products (AGEs) were estimated spectrophotometrically. Inducible nitric oxide synthase (iNOS) and matrix metalloproteinases (MMPs) activity was measured in supernatants by kit method from tissue homogenates. Significantly (<0.05) decreased levels of antioxidants (SOD, CAT, GSH, vitamin C, vitamin E, GPx and GRx) were observed in tissue homogenate of radicular cyst as compared to healthy controls. Higher levels of MDA, AOPPs, AGEs, NO, iNOS LPS and MMP-9 signifies their importance and role in the development/expansion of radicular cyst. Inducible nitric oxide synthase (iNOS) play a key role to stimulate and release of elevated nitric oxide levels in an environment provided by tumor necrosis factor alpha. Lipopolysaccharide directly activates the host cells to secrete MMPs which play a key role in degrading the bone matrix and hence expansion of radicular cyst.

* Corresponding Author: Arif Malik ✉ arifuaaf@yahoo.com

Introduction

Apical inflammatory lesions are repeatedly a concern of dental caries evolution causing pulp necrosis (Nair, 2006). Apical periodontitis is the most common endodontic and inflammatory disease encompasses damage of periradicular tissues due to the interface between pathogen (Bacterial products) and host defense consisting of several cell classes, intracellular messenger, antibodies and effect or molecule. In periodontal tissue variation in inflammatory process are originated predominantly due to etiological mediator i.e. sub-gingival dental plaque. Radicular cyst (RC) is a pathologic cavity wizeded by epithelium, fibrous connective tissue and rare astonishing neoplasm. RC occurs due to the insults of infection, iatrogenic and physical distress, endodontic treatment and damaging effects of root canal filling material to the dental pulp. With the periapical tissue damage resorption of bone adjacent to root of involved teeth also occurs. Pathogenesis of radicular cyst is very complex due to the involvement of multiple factors. State and progression of disease can be restructured and prejudiced by the communication and profusion of pro-inflammatory and anti-inflammatory molecules (Graunaite *et al.*, 2011).

Main stimulus for the proliferation of keratinocytes in lipopolysaccharide (LPS) which is found in the necrotic pulp LPS stimulates the proliferation of keratinocytes directly or indirectly by releasing cytokines from inflammatory cells. LPS directly activates the host cells to secrete MMPs which play a role in degrading the bone matrix and hence expansion of cyst.

The imbalance between cell growth and apoptosis plays major role in RC formation (Loreto *et al.*, 2013 and Meliou *et al.*, 2010). A proapoptotic microenvironment is established in cystic cavity validating decrease in bcl-2 (Anti apoptotic) and increase in bax (Apoptotic) expression causing apoptotic cascade, which assess the manifestation of tumor necrosis factor relating apoptosis inducing ligand, DR5 and caspase-3 in newly formed epithelial layer and connective tissue fibroblast of the RC (Loreto *et al.*, 2013 and Khalifa *et al.*, 2010).

Chemokines play a major role in inflammation by prompting epithelial cell in RC (Duque *et al.*, 2014). For cyst extension polymorphonuclear (PMN) cells drift from capillary connective tissue to the surface of lumen through the channels shaped between epithelial linings of cyst (Schaller *et al.*, 2004). Inflammatory cytokines uphold cyst growth and bone resorption because IL-1, IL-6 and TNF- α was responsible to modulate bone remodeling.

MMPs impact bone resorption and epithelial cell immigration to form RC (Cekici *et al.*, 2014). As the cyst develops bone devastation occurs throughout cyst growth. The expression of receptor activator NFkB-ligand (RANKL) and matrix metalloproteinases (MMPs) were found in cyst cavity which shows the vital role of these molecules in facilitating bone resorption. IL-1 α induce the secretion of MMP-9 and responsible for enzymatic degradation of extracellular matrix and basement membrane results in cyst expansion. IL-1 β , TNF- α , Interferon γ and lipopolysaccharide induce MCP-3 which play a major role in RC pathobiology by inspiring mononuclear chemotaxis (Dezerega *et al.*, 2010). Passable level of lipopolysaccharide is molded by microorganisms from infested root canals which is then egress in high concentration into periapical region. In gingival fibroblast LPS activates nuclear factor-k β (NF-k β) pathway via toll like receptor-4 (TLR-4) and CD14 and secretion of inflammatory cytokines and AP-1 which stimulate PMNs activation for ROS production and increase in MMP concentration by activating osteoclast, eventually results in tissue destruction. Nitric oxide (NO) molecule has become highly reactive free radical by changing the arrangement of one oxygen atom and one nitrogen atom in it. A complex family of enzyme such as nitric oxide synthase (NOS) is responsible for the production of NO (Brennan *et al.*, 2003). NO has three iso-forms such as NOS1, NOS2 and NOS3. NOS1 and NOS3 are constitutive and NOS2 is an independent of calcium and inducible so called inducible nitric oxide synthase (iNOS). NO with the connotation of cytokines regulates the process of inflammation in RC (Takeichi *et al.*, 1998 and Hama *et al.*, 2006).

Peroxynitrite is a strong oxidant which causes lipid peroxidation, oxidative modification of nitrogenous bases cause damage to nucleic acid and inactivation of various enzymes. It can cause damage to mitochondria either by direct oxidation reaction or by the production of free-radicals. Free-radicals produced in the vicinity of mitochondria cause oxidation of main components of respiratory chain components resulting in apoptosis (Novo and Parola, 2008). NO derived from macrophages after bacterial LPS and inflammatory cytokines such as TNF- α , IL-1 β and IFN- γ stimulation may enhance bone loss by boosting the cytokine induced MMP-1 production in osteoblasts. NO also cause iron loss inside the cell, apoptosis, inhibition of mitochondrial function and DNA damage (Matsumoto *et al.*, 2007).

Reactive oxygen species (ROS) and free radicals are essential for normal biological process in low concentration but their higher concentration cause tissue injury. Bacterial pathogen in dental plaque stimulates the release of pro-inflammatory cytokines *i.e* TNF- α and various interleukins by host cell which attract polymorphonucleocytes (PMNs) towards the site of infection. PMNs strive with bacterial pathogen by producing proteolytic enzymes and O₂ by oxidative burst. In periodontal pocket PMN during inflammatory response leads to the generation of ROS which are highly destructive in nature and results in ROS oxidation products, elevation of iron and copper ions which catalyze production of most reactive radical species and imbalance in oxidant/antioxidant activity (Waddington *et al.*, 2000). Antioxidant defense system has developed in human body to detoxify ROS and transform them into less reactive species. This antioxidant defense system comprises endogenous antioxidants such as vitamin A, B, C, E and enzymatic antioxidants such as superoxide dismutase (SOD) and catalase.

The present study depicted the role several prophetic factors which are found to be involved in the development/expansion of radicular cyst. The role of proinflammatory cytokines were discussed previously but the relation of reactive oxygen species (ROS) in

the development and expansion of radicular cyst (RC) still remains unclear. Moreover the present study states the effects and significance of NOS in the progression of disease. Intrusive effects of MMPs *i.e.*, (MMP-3 and 9) were also found to play a significant role in the emergence of the disease. Sample size of the current study is major limiting factor and number cytokines, MMPs are still to be screened for stronger correlations among them.

Materials and methods

The present study was performed in University College of Dentistry Lahore and Institute of molecular biology and biotechnology (IMBB), The University of Lahore. Forty Patients with periapical granulomas and radicular cysts and twenty samples of normal pulp were drawn from teeth for controls.

Inclusion criteria

Patients with CAL (Clinical Attachment Loss) of greater than 3mm, Probing depth of greater than 5mm Bleeding on probing and radiographic evidence of periapical round or ovoid well defined radiolucency's.

Exclusion criteria

Patients with any congenital diseases, diabetic and HIV patients were excluded out.

Biochemical analysis

Glutathione (GSH), Glutathione reductase (GRx), Glutathione peroxidase (GPx), Catalase (CAT), Malondialdehyde (MDA), superoxide dismutase (SOD), Vitamin-C, Vitamin-E, Nitric oxide (NO), Lipopolysaccharides (LPS), advanced oxidation protein products (AOPPs), advanced glycation end products (AGEs) were estimated spectrophotometrically. While, activity of iNOS and MMPs were measured by the commercially available ELISA kits.

Statistical analysis

Statistical analysis (Student t-test) was performed using SPSS (Ver.16). The data will be expressed as Mean \pm SD. Pearsonian correlation coefficient (*r*) were considered significant at (≤ 0.05).

Results

Data presented in (Table 01 and Fig. 01A-01B) shows significantly (<0.05) lower levels of SOD (U/ml), CAT (U/L) and GSH ($\mu\text{mol/L}$) (0.816 ± 0.012 , 1.023 ± 0.039 and 3.065 ± 0.9658) were observed as compared to normal dental tissue homogenates (0.216 ± 0.016 , 2.09 ± 0.165 and 9.09 ± 1.23). Higher levels of MDA (4.956 ± 1.02 Vs control $0.95\pm0.23\text{nmol/ml}$) were recorded in patients with radicular cyst ($p=0.0165$). Significantly ($p<0.05$, Table 01) raised levels of AOPPs (mmol/L) AGEs (AU), NO ($\mu\text{mol/L}$), iNOS(IU/ml),

LPS (pg/ml) and MMP-9 (ng/ml) (1.56 ± 0.086 , 4.026 ± 0.326 , 41.26 ± 3.26 , 19.36 ± 1.99 , 125.25 ± 7.66 and 1.64 ± 0.15) as compared to normal (0.42 ± 0.095 , 1.05 ± 0.165 , 15.26 ± 2.02 , 7.98 ± 1.065 , 23.26 ± 4.26 and 0.619 ± 0.035) were also noted in RC patients but very low levels of vitamin C (nmol/L), E (nmol/L), GPx ($\mu\text{mol/L}$) and GRx ($\mu\text{mol/L}$) was present in RC subjects (0.356 ± 0.0156 , 0.2568 ± 0.031 , 3.065 ± 0.65 and 1.66 ± 0.064) as compared to healthy controls (0.532 ± 0.0326 , 0.325 ± 0.023 , 6.265 ± 0.29 and 2.06 ± 0.086).

Table 01. Levels of prognostic variables in radicular cyst having potential role in its development.

Variables	Control (n=20)	Subject (n=40)	P- Value
MDA (nmol/ml)	0.95±0.23	4.956±1.02	0.0165
SOD (U/ml)	0.216±0.016	0.816±0.012	0.0235
GSH ($\mu\text{mol/L}$)	9.09±1.23	3.065±0.9658	0.0056
CAT (U/L)	2.09±0.165	1.023±0.039	0.0325
AOPPs (mmol/L)	0.42±0.095	1.56±0.086	0.0125
AGEs (AU)	1.05±0.165	4.026±0.326	0.006
MMP-9 (ng/ml)	0.619±0.035	1.64±0.15	0.016
Vit-C (nmol/L)	0.532±0.0326	0.356±0.0156	0.033
Vit-E (nmol/L)	0.325±0.023	0.2568±0.031	0.0416
NO ($\mu\text{mol/L}$)	15.26±2.02	41.26±3.26	0.000
iNOS (IU/ml)	7.98±1.065	19.36±1.99	0.000
Lipopolysaccharides (pg/ml)	23.26±4.26	125.25±7.66	0.0016
GPx($\mu\text{mol/L}$)	6.265±0.29	3.065±0.65	0.0195
GRx($\mu\text{mol/L}$)	2.06±0.086	1.66±0.064	0.008

Table 02. Pearson s' correlation coefficients matrix of different variables in radicular cyst development.

VAR	MDA	SOD	GSH	CAT	AOPPs	AGEs	MMP-9	Vit-C	Vit-E	NO	iNOS	LPS	GPx	GRx
MDA	1	-0.56*	-0.42*	0.32	0.395	0.426	0.165	0.326	0.162	0.865**	-0.659	0.564	-0.42*	-0.55*
SOD		1	0.62*	0.12	0.232	0.325	0.123	0.563	0.125	-0.76**	-0.58*	-0.66*	-0.54*	-0.49*
GSH			1	0.219	0.325	0.231	0.125	0.326	0.235	-0.516*	-0.61*	-0.54*	0.71**	0.85**
CAT				1	0.195	0.095	0.23	0.432	0.125	0.114	0.065	0.153	0.265	0.144
AOPPs					1	0.59**	0.412	0.61*	0.523	0.162	0.122	0.391	0.165	0.060
AGEs						1	0.316	0.58*	0.432	0.125	0.239	0.265	0.235	0.234
Vit-A							1	0.195	0.32	0.012	0.224	0.124	0.235	0.165
Vit-C								1	0.01	0.426*	0.432	0.114	0.111	0.321
Vit-E									1	0.123	0.091	0.169	0.316	0.220
NO										1	0.84**	0.76***	-0.49*	-0.39*
iNOS											1	0.618**	-0.51*	-0.41*
LPS												1	-0.42*	0.513*
GPx													1	0.432*
GRx														1

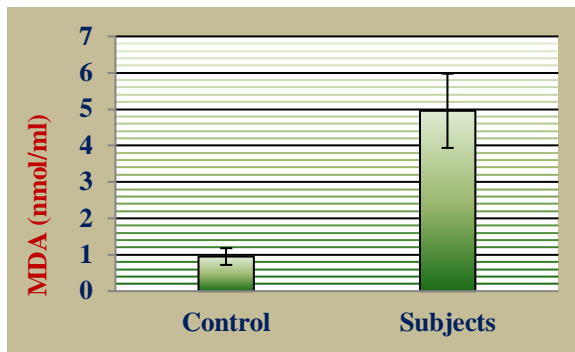


Fig. (A)

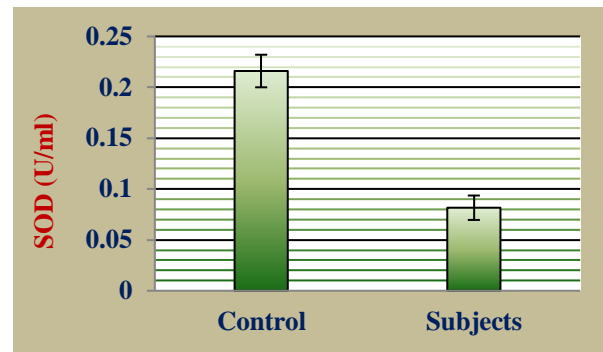


Fig. (B)

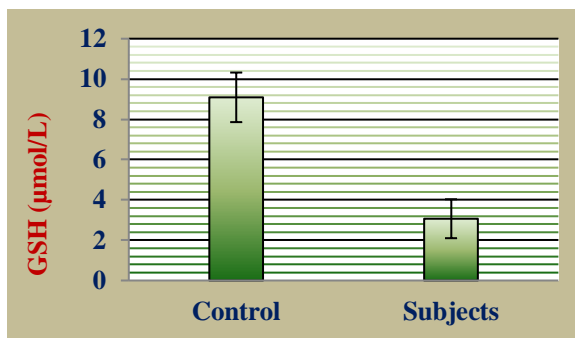


Fig. (C)

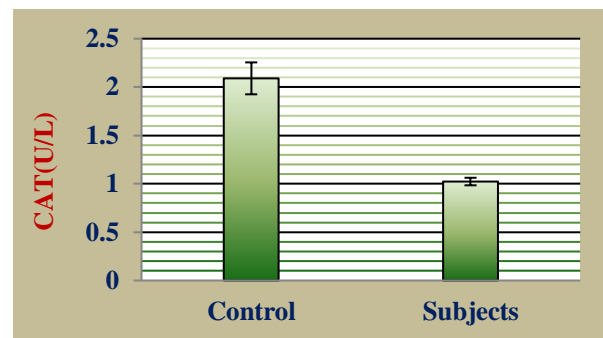


Fig. (D)

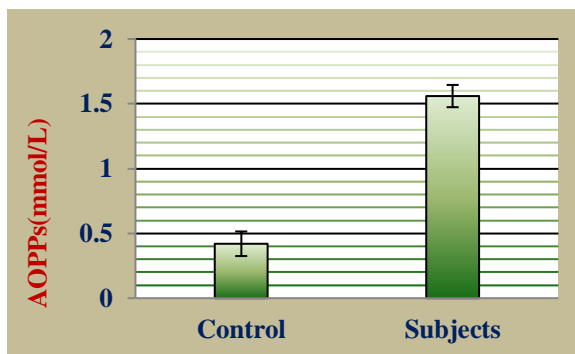


Fig. (E)

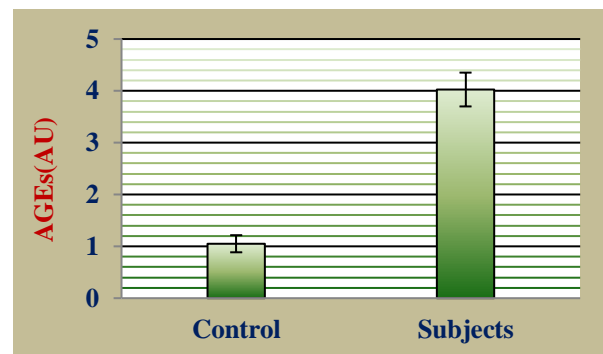


Fig. (F)

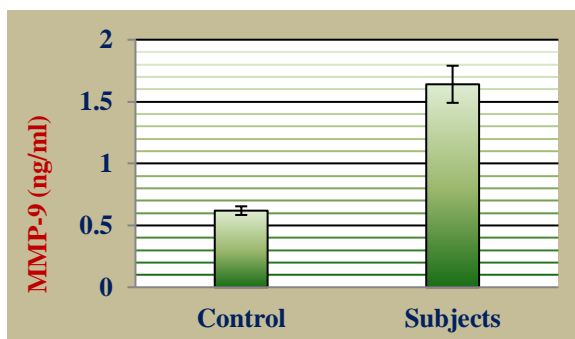


Fig. (G)

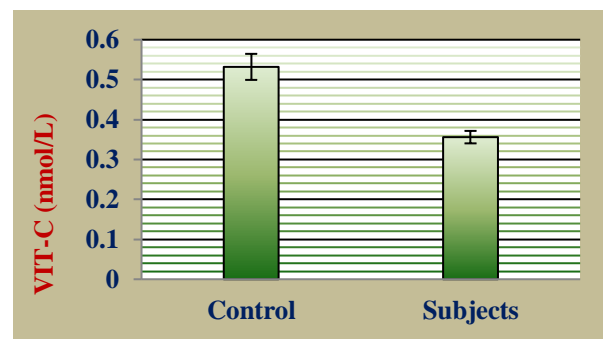


Fig. (H)

Fig. 01. A) profile of different prognostic variables in radicular cyst versus controls.

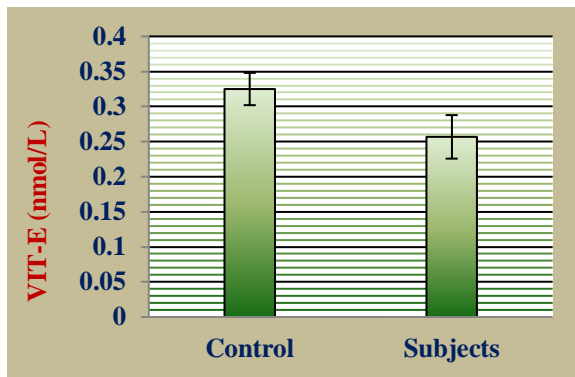


Fig. (I)

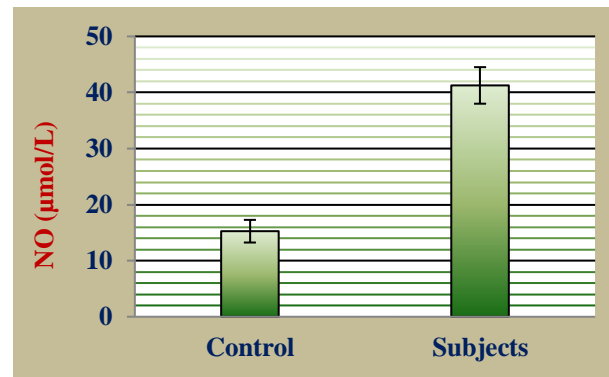


Fig. (J)

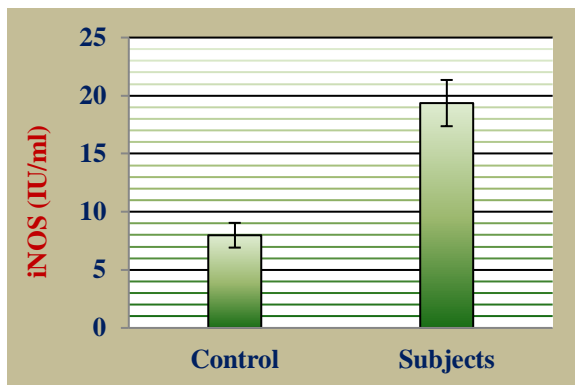


Fig. (K)

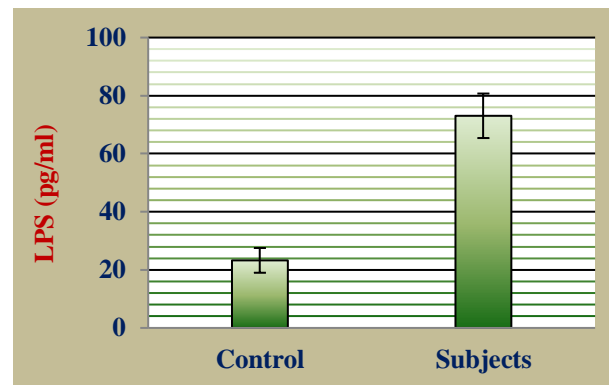


Fig. (L)

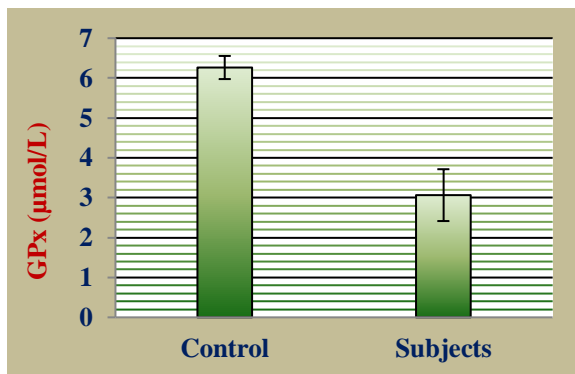


Fig. (M)

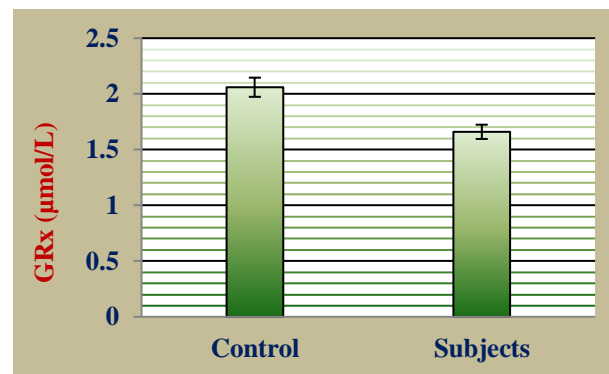


Fig. (N)

Fig. 01. B) Profile of different prognostic variables in radicular cyst versus controls.

Discussion

Radicular cyst is the most common cyst involving the jaw derived from cell rest of Malassez. Trauma, infection, necrotic pulp and endodontic failure may lead to the formation of radicular cyst (Lin *et al.*, 2007). The rest of Malassez begin to proliferate under the influence of inflammation in necrotic pulp. The microorganisms residing in the root canal secrete endotoxin and invite the inflammatory cells around

the periapex. These inflammatory cells secrete the cytokines and growth factors which stimulate the synthesis of residual epithelial cells in periodontal ligament. The main stimulus for the proliferation of keratinocytes is lipopolysaccharide (LPS) which is found in necrotic pulp. LPS stimulates the proliferation of keratinocytes directly or indirectly by releasing cytokines from inflammatory cells. The macrophages, lymphocytes, fibroblasts and neutrophils

release proinflammatory cytokines, chemokines and growth factors in the periapical area. Interleukins (IL1, IL3, IL4, IL6), prostaglandins, transforming growth factor-alpha (TGF- α), tumor necrosis factor-alpha (TNF- α), interferon (IFN) and MMPs are identified in radicular cyst. All these molecules upregulate the epidermal growth factor (EGF) receptors and interaction of epidermal growth factor (EGF) receptor and its ligand stimulates the proliferation of keratinocytes around apex of tooth. These proinflammatory cytokines also upregulate the expression of keratinocyte growth factor (KGF) and insulin like growth factor (IGF) ultimately stimulating the proliferation of rest of Malassez (Loreto *et al.*, 2013).

The cyst expands once it is formed and increases hydrostatic pressure and bone resorption around the apex contribute the enlargement of cyst. The osmotic pressure of cyst is increased due to accumulation of high molecular weight proteins in lumen which comes from inflammatory exudates. Mast cells also contribute to increase the osmotic pressure of cyst by secreting heparin inside the lumen. Mast cells also secrete hydrolytic enzymes and histamine. Hydrolytic enzymes degrade the extracellular matrix and facilitate its transportation inside the lumen. Histamine causes increased permeability of vessels and serum proteins are transported to inflammatory area. Many cells including macrophages, fibroblast, keratinocytes and lymphocytes secrete vascular endothelial growth factor (VEGF). VEGF increases the permeability of vessels with the release of inflammatory cells and proteins. Hepatocyte growth factor (HGF) is also expressed in periapical cyst. HGF stimulates the proliferation of epithelial cells in the lining and its invasion into the adjacent connective tissue (Krafts, 2010). Bone resorption around the apex is the most destructive phenomena during the cyst expansion.

Osteoclasts are the effector cells of bone resorption and are activated by proinflammatory cytokines. The ratio of Receptor activator of NF κ B-ligand (RANKL) is increased in radicular cyst and it binds its receptor RANK on the surface of osteoclast and promotes the

differentiation of mature osteoclasts from preosteoclasts. Activated osteoclasts by NF κ B pathway resorb bone and cyst expands (Yalei *et al.*, 2009). MMPs are overexpressed in destructive bone and chronic inflammatory lesions. MMP-2, MMP-8 and MMP-9 are overexpressed in radicular cyst. Proinflammatory cytokines stimulate the neutrophils, keratinocytes, macrophages and fibroblasts to secrete the MMPs. Lipopolysaccharide (LPS) directly activates the host cells to secrete MMPs which play a role in degrading the bone matrix and hence expansion of cyst (Graves *et al.*, 2011). Cytokine promoted NO release has the potential to decrease cell proliferation and stimulate apoptosis. A significant correlation (Table 02) was observed between LPS and NO (LPS Vs. NO $r=0.76^{***}$). NO produced by iNOS predominantly activates proinflammatory transcription factor NF- κ B in return and only iNOS has the potential to stimulate release of elevated levels of NO in an environment provided by TNF- α and LPS. Strong significant correlation ($p<0.05$) was recorded between NO and iNOS (NO Vs. iNOS $r=0.84^{**}$) and between LPS and iNOS (LPS Vs. iNOS $r=0.618^{**}$) signifies their potential role in the pathogenesis of radicular cyst development (Benzie and Strain, 1996).

Reactive oxygen species (ROS) are highly reactive and can damage the cells by modification and inactivation of proteins, lipids, DNA and RNA. O_2^- , NO and H_2O_2 play an important role in inflammation and host defence (Gelissen *et al.*, 2011). Significant inverse correlation was professed between superoxide dismutase (SOD) and inducible nitric oxide synthase (iNOS), nitric oxide (NO), lipopolysaccharide (LPS) [(SOD Vs NO $r=-0.76^{**}$), (SOD Vs iNOS $r=-0.58^*$) and (SOD Vs LPS $r=-0.66^*$)] respectively (Table:02). O_2^- is mainly produced by neutrophils and causes damage to cells and tissues in inflammatory diseases. In periapical lesions bone loss is seen due to alteration in balance between O_2^- production and its elimination. ROS activate proinflammatory transcription factors NF- κ B by stimulating RANKL and AP-1 hence exaggerating the inflammatory response (Wang *et al.*, 2015). As far as inflammatory diseases of oral cavity pertaining to the odontogenic tissues are concerned ROS play a pivotal role in the

degradation of extracellular matrix components and accentuation of the inflammatory response, specifically OH radical can inflict potential damage to the supporting connective tissues and macromolecules of great biological significance in an attempt to balance its unpaired electronic status (Hasturk *et al.*, 2012). Significant ($p < 0.05$) inverse correlation was also observed between GSH, NO, and LPS (GSHVs NO $r = -0.516^*$), and (GSHVs LPS $r = -0.54^*$) respectively (Table 02).

Conclusion

As far as inflammatory diseases of oral cavity pertaining to the odontogenic tissues are concerned reactive oxygen species (ROS) play a pivotal role in the degradation of extracellular matrix components and accentuation of the inflammatory response, specifically OH⁻ radical can inflict potential damage to the supporting connective tissues and macromolecules of great biological significance in an attempt to balance its unpaired electronic status. Nitric oxide (NO) produced by inducible nitric oxide (iNOS) predominantly activates proinflammatory transcription factors in return. iNOS has the potential to stimulate release of elevated levels of NO in an environment provided by tumor necrosis factor alpha (TNF- α) and lipopolysaccharides (LPS). In periapical lesions bone loss is seen due to alteration in balance between O₂⁻ production and its elimination. ROS activate proinflammatory transcription factors NF- κ B by stimulating RANKL and AP-1 hence exaggerating the inflammatory response. Proinflammatory cytokines stimulate the neutrophils, keratinocytes, macrophages and fibroblasts to secrete the matrix metalloproteinases (MMPs). Lipopolysaccharide (LPS) directly activates the host cells to secrete MMPs which play a key role in degrading the bone matrix and hence expansion of radicular cyst (RC).

Acknowledgements

The authors are highly thankful for the valuable contribution of Prof. Dr. M.H. Qazi, Director Center for Research in Molecular Medicine (CRiMM), The University of Lahore-Pakistan regarding financial support and critical review of the manuscript.

Conflict of interest

Authors declares no conflict of interest

References

- Benzie IF, Strain JJ.** 1996. The ferric reducing ability of plasma (FRAP) as a measure of "antioxidant power": the FRAP assay. *Anal Biochem* **239**, 70-76.
- Brannan PA, Thomas GJ, Langdon JD.** 2003. The role of nitric oxide in oral diseases. *Arch Oral Biol* **48**, 93-100.
- Cekici A, Kantarci A, Hasturk H, Thomas E.** 2014. Inflammatory and immune pathways in the pathogenesis of periodontal disease. *Periodontol* **64(1)**, 57-80.
- Dezerega A, Osorio C, Madones J.** 2010. Monocyte chemotactic protein-3: possible involvement in apical periodontitis chemotaxis. *Int Endod J* **43**, 902-908.
- Duque GA, Descoteaux A.** 2014. Macrophage cytokines: involvement in immunity and infectious diseases. *Front Immunol* **5**, 491.
- Formigli L, Orlandini SZ, Tonelli P, Giannelli M, Martini M, Brandi ML, Bergamini M, Orlandini GE.** 1995. Osteolytic processes in human radicular cysts: morphological and biochemical results. *J Oral Pathol Med* **24(5)**, 216-220.
- Gelisgen R, Genc H, Kayali R, Oncul M, Benian A, Guralp O.** 2011. Protein oxidation markers in women with and without gestational diabetes mellitus: a possible relation with paraoxonase activity. *Diabetes Res Clin Pract* **94**, 404-409.
- Graunaite I, Lodiene G, Maciulskiene V.** 2011. Pathogenesis of apical periodontitis: a review. *Oral Maxillofac J* **2**, 4-1.
- Graves DT, Oates T, Gustavo PG.** 2011. Review of osteo-immunology and the host response in endodontic and periodontal lesions. *Journal of oral microbiology* **3**, 2000-2297.

- Hama S, Takeichi O, Hayashi M, Komiyama K, Ito K.** 2006. Co-production of vascular endothelial cadherin and inducible nitric oxide synthase by endothelial cells in periapical granuloma. *Int Endod J* **93**, 179-184.
- Hasturk H, Kantarci A, Thomas EVD.** 2012. Oral Inflammatory Disease and Systemic inflammation: Role of the Macrophage. *Front Immunol* **3**, 118.
- Janda J, Work E.** 1971. Colorimetric estimation of lipopolysaccharides. *FEBS Letters* **16(4)**, 343-345.
- Khalifa GA, Shokier HM, Abo-Hager EA.** 2010. Evaluation of neoplastic nature of keratocystic odontogenic tumor versus ameloblastoma. *J Egypt Natl CancInst* **22**, 61-72.
- Krafts KP.** 2010. Tissue Repair: The hidden drama. *Organogenesis* **6**, 225-233.
- Lin LM, Huang GT, Rosenberg PA.** 2007. Proliferation of epithelial cell rests, formation of apical cysts, and regression of apical cysts after periapical wound healing. *J Endod* **33(8)**, 908-916.
- Loreto C, Galanti C, Leondardi R.** 2013. Possible role of apoptosis in the pathogenesis and clinical evolution of radicular cyst: an Immunohistochemical study. *IntEndod J* **46**, 642-648.
- Masanori H, Hayakawa Y, Kosugi H, Koizumi F.** 1998. Localization of mRNA for inflammatory cytokines in radicular cyst tissue by in situ hybridization and induction of inflammatory cytokines by human gingival fibroblasts in response to radicular cyst contents. *J Oral Pathol Med* **27**, 399-404.
- Matsumoto MA, Ribeiro DA.** 2007. Inducible nitric oxide expression correlates with the level of inflammation in periapical cysts. *Eur J Dent* **1**, 212-215.
- Mc Kee M, Scavone C, Nathanson JA.** 1994. Nitric oxide, c GMP, and hormone regulation of active sodium transport. *Proceedings of the National Academy of Sciences, USA* **91**, 12056-12060.
- Meliou E, Kerezoudis N, Tosios K, Kiaris H.** 2010. Notch 1 receptor, delta 1 ligand and HES 1 transcription factor are expressed in the lining epithelium of periapical cysts (pre-liminary study). *Open Dent J* **4**, 153-158.
- Nair PN.** 2006. On the causes of persistent apical periodontitis: a review. *Int Endod J* **39**, 249-281.
- Novo E, Parola M.** 2008. Redox mechanisms in hepatic chronic wound healing and fibrogenesis. *Fibrogenesis Tissue Repair* **13(1)**, 5.
- Schaller MI, Boeld U, Oberbauer S, Hamm G, Hube B, Korting HC.** 2004. Polymorphonuclear leukocytes (PMNs) induce protective Th1-type cytokine epithelial responses in an in vitro model of oral candidosis. *Microbiology* **150(9)**, 2807-2813.
- Takeichi O, Saito I, Okamoto Y, Tsurumachi T, Satio T, Saito T.** 1998. Cytokine regulation on the synthesis of nitric oxide in vivo by chronically infected human polymorphonuclear leucocytes. *Immunology* **93**, 275-80.
- Waddington RJ, Moseley R, Embery G.** 2000. Reactive oxygen species: a potential role in the pathogenesis of periodontal disease. *Oral diseases J* **6**, 138-151.
- Wang T, Liu Q, Zhou L, Yuan JB, Lin X, Zeng R, Liang X, Zhao J, Xu J.** 2015. Andrographolide Inhibits Ovariectomy-Induced Bone Loss via the Suppression of RANKL Signaling Pathways. *Int J MolSci* **16(11)**, 27440-27481.
- Yalei WU, Humphrey MB, Nakamura MC.** 2009. Osteoclasts-the innate immune cells of the bone. *Autoimmunity* **41(3)**, 183-194.