



## RESEARCH PAPER

## OPEN ACCESS

## Hypodontia and Cleft Lip Palate; A Consequence of Homozygous Missense Mutation in *PAX9* Gene

Agha Muhammad Raza\*<sup>1</sup>, Nasrullah Mengal<sup>2</sup>, Muhammad Nawaz<sup>2</sup>,  
Muhammad Saeed<sup>3</sup>, Abdul Wali<sup>4</sup>, Jamil Ahmad<sup>4</sup>

<sup>1</sup>Department of Microbiology, BUIITEMS, Quetta, Pakistan

<sup>2</sup>Department of Orthodontics, Bolan Medical College, Quetta, Pakistan

<sup>3</sup>Department of Environmental Science, BUIITEMS, Quetta, Pakistan

<sup>4</sup>Department of Biotechnology, BUIITEMS, Quetta, Pakistan

**Key words:** Hypodontia, Cleft lip palate, *PAX9* and homozygous mutation

<http://dx.doi.org/10.12692/ijb/10.3.382-387>

Article published on March 31, 2017

### Abstract

The congenital absence of teeth is one of the major and commonest dental developmental disorders seen in humans. Hypodontia is used as a collective term for congenitally absence of one to six teeth, excluding the third molars. The knowledge of the etiological basis of inherited tooth loss remains poor, thus far two genes (*PAX9* and *MSX1*) have been identified as the major causes of hypodontia. Here, we investigated two Pakistani families affected with hypodontia and cleft lip palate. Radiographic examination revealed missing of multiple permanent teeth in affected individuals of both families. Blood samples (5ml) were collected from all affected individuals, their parents and normal siblings. Genomic DNA was extracted by using inorganic method. All the three coding exons of *PAX9* (NM\_006194) were amplified and sequenced. Sequencing of the *PAX9* coding exons and splice sites showed a homozygous missense substitution in exon 3 (c. 718C>G; p.Ala240Pro) in the affected individuals of both the families. This mutation co-segregated with hypodontia and cleft lip palate in the respective families. As a conclusion, we identified a missense substitution (p.Ala240Pro) in gene *PAX9* in two different Pakistani families with hypodontia and cleft lip palate.

\* Corresponding Author: Agha Muhammad Raza ✉ [doctorsmartpc@live.com](mailto:doctorsmartpc@live.com)

## Introduction

Developmental dental anomalies are considered as an important morphological and structural dental disparity. Their etiology is complex resulting from the influence of genetic, epigenetic and environmental factors. Although genetic defects have been considered to be the most influential factor (Vaniet *et al.*, 2016). Several homeobox genes have been implicated in the etiology of hypodontia including *MSX1*, *MSX2*, *PAX9*, (Cobourne, 2007), *WNT10A* and *AXIN2* (Mostowska, *et al.*, 2015). Based on severity, congenital tooth agenesis is classified into hypodontia, oligodontia and anodontia. The term hypodontia is used in a narrow sense when the number of missing teeth is one or a few. Oligodontia is defined as missing a large number of teeth. Anodontia is an extreme case, denoting complete absence of teeth. Incisors and premolars are the most frequently missing teeth (Arte *et al.*, 2001). Hypodontia can be classified as either non-syndromic (isolated) or syndromic based on the presence of other genetic abnormalities (Gorlin and Hennekam, 1990). Other anomalies associated with hypodontia include small tooth size (microdontia), large tooth size (macrodontia) and anomalies in tooth shape (McKeown *et al.*, 2002).

Literature suggests that *PAX9* gene is one of the main responsible genes for hypodontia. The *PAX9* gene is located on chromosome 14q13.3 (36,657,568 bp to 36,677,807 bp). This gene is a member of the paired box (PAX) family of transcription factors. Members of this gene family typically contain a paired box domain, an octapeptide, and a paired-type homeodomain. These genes play critical roles during fetal development and cancer growth. *PAX9* gene is an associated finding in at least 49 syndromes listed in the Online Mendelian Inheritance in Man database (Boyadjiev and Jabs, 2000) implying some factors involved in tooth development have a wider role within the human body. It plays a primary role in regulating the mesenchymal-epithelial interactions (Zhou *et al.*, 2013). *PAX9* mutation causes tooth missing in both human and mice (Swartz *et al.*, 2011).

The main purpose of this study and research work was to identify the phenotype of hypodontia as well as to locate the genetic loci responsible for hypodontia in the Balochistan province of Pakistan. Here, we investigated two families affected with hypodontia and cleft lip palate. Mutational analysis of *PAX9* by exon sequencing identified a homozygous missense mutation (c.718C>G). The resulting phenotype is distinct from previously reported hypodontia and cleft lip palate caused by mutation in *PAX9* gene.

## Materials and methods

This study was approved by institutional review board (IRB # 00007818) at the Department of Biotechnology, BUITEMS, Quetta, Balochistan, Pakistan and conducted according to the tenets of the declaration of Helsinki. Written informed consent was obtained from all participants and their parents. The diagnosis of hypodontia and cleft lip palate was based on clinical intra oral examination, panoramic and cephalometric X-rays and cast model analysis. Radiographic examination revealed missing of multiple permanent teeth in affected individuals of both families.

### Blood Collection and DNA Extraction

Blood samples (5 ml) were collected from all affected individuals, their parents and normal siblings. Genomic DNA was extracted by using inorganic method which involved lysis of red blood cells, followed by protein digestion and DNA precipitation. Primers for coding sequences of *PAX9* gene were designed using Primer3 plus computer program ([www.bioinformatics.nl/cgi-bin/primer3plus/primer3plus.cgi/](http://www.bioinformatics.nl/cgi-bin/primer3plus/primer3plus.cgi/)) (Table 1.).

**Table 1.** Sequence of primers used for PCR amplification of human *PAX9* exons and PCR conditions.

Exon	Left Primer (5' → 3')	Right Primer (3' → 5')	Product Size	Ann. Temp
2	CATCCGACCCGTGTGACATC	AGGATGTCGGTGACGGAGT	498	61 °C
3	TGGAAAGGCCTACTCTGAGG	GAAGGATCTGGCTCGTAACA	498	61 °C
4	TCAGAGCATTGCTGGCTTAC	ATGTGAGACCTGGGAAATGG	441	62 °C

### Polymerase Chain Reaction

Three coding exons of *PAX9* (NM\_006194) were amplified and sequenced. PCR products were amplified using 50 ng of genomic.

DNA in a 25 µl reaction mixture containing 10 pmol of forward and reverse primers, 0.2 mmol/l dNTPs, 10 mmol/l Tris-HCl, 50 mmol/l KCl, 1.5 mmol/l MgCl<sub>2</sub>, and 0.5 U *Taq* polymerase (Invitrogen Corp. Carlsbad, CA, USA). Initial denaturation was carried out at 93°C for 3 min, followed by 30 cycles at 93°C for 45 s, 61°C and 62°C for 30 s and 72°C for 45 s, and a final extension step at 72°C for 10 min. for all exons.

PCR products were digested with exonuclease I and shrimp alkaline phosphatase (Fermentas Life Sciences, Glen Burnie, MD, USA), and sequenced bi-directionally using the Big Dye Terminator v.3.1 Kit (Applied Biosystems, Darmstadt, Germany) on an ABI 3730 DNA capillary sequencer. The sequencing data was analyzed using BioEdit v7.0.9 software ([www.mbio.ncsu.edu/bioedit/page2.html](http://www.mbio.ncsu.edu/bioedit/page2.html)).

The identified mutation was checked in public databases, namely dbSNP ([www.ncbi.nlm.nih.gov/SNP/](http://www.ncbi.nlm.nih.gov/SNP/)), 1000 Genomes database ([www.browsers.1000genomes.org/index.html](http://www.browsers.1000genomes.org/index.html)), NHLBI Exome Variant Server

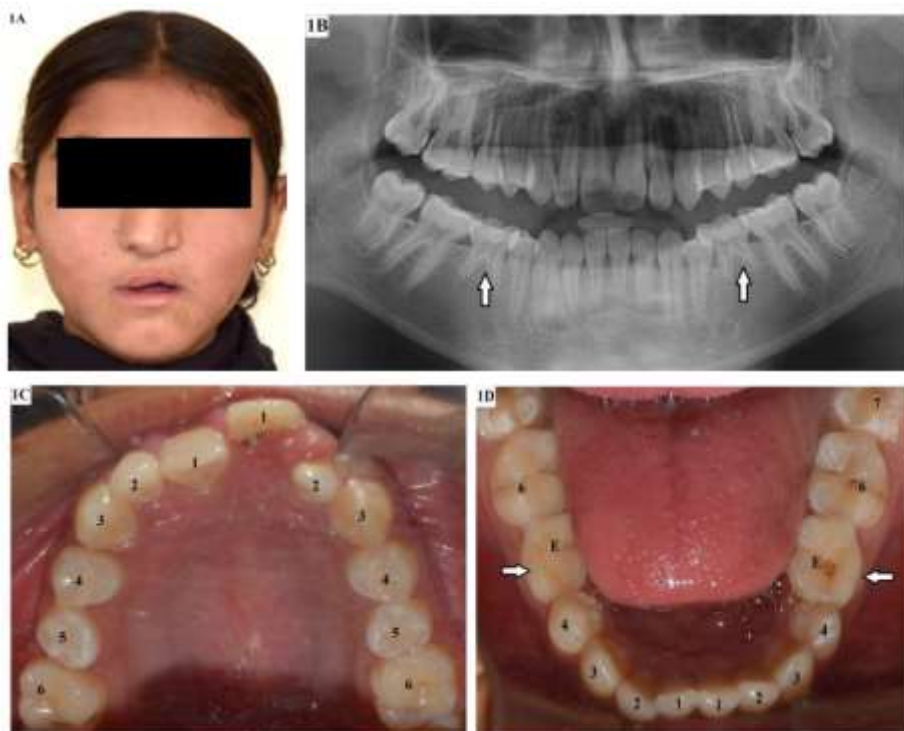
([www.evs.gs.washington.edu/EVS/](http://www.evs.gs.washington.edu/EVS/)) and the Human Gene Mutation Database ([www.hgmd.cf.ac.uk/ac/index.php](http://www.hgmd.cf.ac.uk/ac/index.php)).

## Results

We studied two families with hypodontia and cleft lip palate, originating from Balochistan. In family 1, two affected individuals were born to normal parents. The elder affected individual was 15 year female with convex profile (Fig 1A).

She is a unilateral cleft patient with skeletal class II and normal vertical growth pattern with increased lower anterior facial height (LAFH) i.e. 57.1% and increased total posterior facial height (TPFH) i.e. 70.5%. Lips are incompetent with decreased nasolabial angle and normal lip relation to E and S plane. Lower incisors have normal inclination and upper incisors are proclined. The molars and canines on both sides are in class II relationship with each other.

There are two permanent teeth missing in the both arches, i.e. both lower second premolars (tooth # 35 and 45) excluding all third molars (Fig 1B – 1D).



**Fig. 1.** (A) Affected individual of family 1 (B) OPG X-rays of affected individual showing *two permanent teeth missing in upper arch i.e. both upper lateral incisors* (tooth number 12 & 22), (C) picture of upper arch (D) Picture of lower arch.

In family 2, two affected individuals were born to normal parents. The affected elder individual was 11 year old female with cleft lip and palate having concave profile (Fig 2A). She is a unilateral cleft patient with skeletal class II and retrusive mandible.

All permanent molars are in class I and canine are in class II relationship with each other. Anterior cross bite is present at upper right central incisor position with reverse over jet and left central incisor is normal in position with positive over jet of upper 2.5mm.

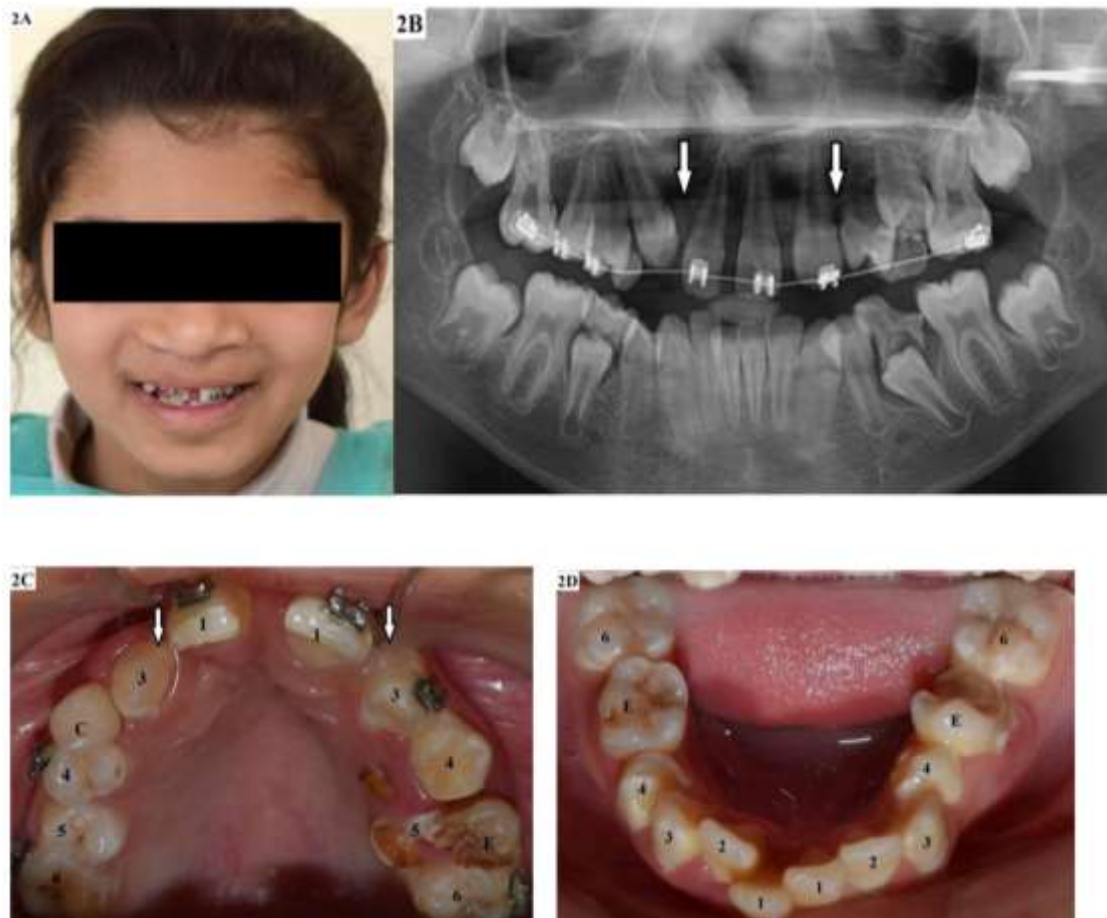Deep bite is 25% (overlapping the lower central incisors) and deep curve of spee is 2.5mm. The upper incisors are retro lined and lower incisors are proclined. The permanent 3rd molars in lower arch and all 2nd molar in both arches are in the developing stage. Midline diastema is 3.5mm.

There are two permanent teeth missing in upper arch i.e. both upper lateral incisors (tooth # 12 and 22), excluding all third molars (Fig 2B - 2D).

Sequencing of the *PAX9* coding exons and splice sites showed a homozygous missense substitution in exon 3 (c. 718C>G; p.Ala240Pro) in the affected individuals of family1 and 2(Fig 3A).

This mutation co-segregated with hypodontia in the respective families and were absent from 100 Pakistani control alleles as determined by sequencing and public databases.

Sequence homology search for *PAX9* indicates that the substituted alanine residue is conserved across different species (Fig. 3B), which suggests that this amino acid is important for the *PAX9* function.



**Fig. 2.** (A) Affected individual of family 2 (B) OPG X-rays of affected individual showing *two permanent teeth missing in the lower arches, i.e. both lower second premolars* (tooth number 35 & 45), (C) picture of upper arch (D) Picture of lower arch.



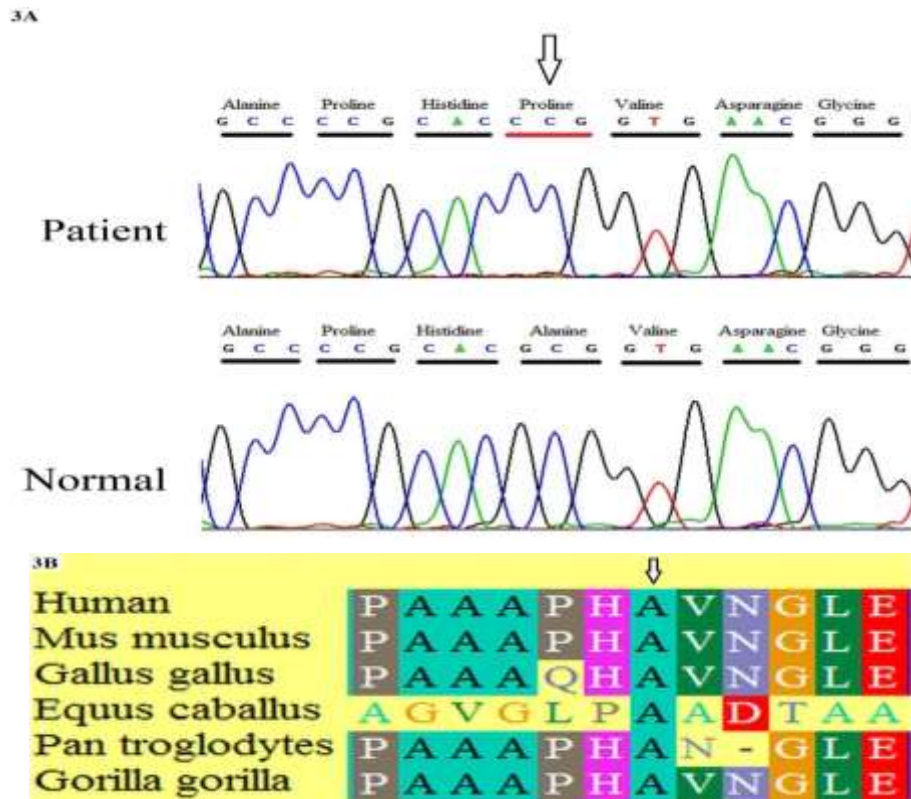


Fig. 3. (A) Sequence analysis of PAX9 exon 3 showing homozygous c.718G>C transition predicting the amino acid substitution p. Ala 240 Pro. (B) Sequence comparison of all PAX9 sequences from different species showing that alanine at position 240 is conserved.

### Discussion

We have identified a *PAX9* homozygous missense mutation in individuals with hypodontia and cleft lip palate from two different Pakistani families. The mutation results in the substitution of proline for alanine in exon 3 of *PAX9* gene. This mutation appeared in affected members of both families, whereas all unaffected family members were negative for this variant. In humans, thirty two *PAX9* mutations have been identified including 21 missense/nonsense, 6 insertion/deletions and 2 for complex re-arrangements ([www.hgmd.cf.ac.uk](http://www.hgmd.cf.ac.uk)).

Hypodontia patient may present with different types of chief complaints, but the most frequent are aesthetic problem, mastication problem and speech problem. In our study the patients were complaining of aesthetic problem. As it is clear from the results, that due to the absence of some teeth, there are empty spaces in between teeth in upper arch as well as lower arch. The diastema in between teeth is the main embracing factor for the patients.

The most common tooth missing in this study was the wisdom third molar tooth, followed by lateral incisors and then second premolars, whereas, no tooth agenesis was seen in canines, first and second molars. It was also observed that pattern of tooth absentia was bilaterally equal, whereas, hypodontia in respect of maxillary or mandibular arches, the anterior teeth were found absent in maxillary upper arch.

The cleft lip palate was found in the patients of both families. Due to missing premolar teeth bilaterally, in patient of family 1, there is a decrease in the lower arch length and width due to which the mandible is retruded and the patient appear with convex profile, whereas the patient of family 2 presented with concave facial profile because of missing upper maxillary lateral incisors on both sides of the arch, which produces a decrease in the arch length and width of maxilla giving a concave facial profile. Deepening of the middle face. An association has been speculated between missing teeth, delayed tooth development, and tooth size.

Based on previous studies, it seems that the more teeth are missing, the greater delay of development for the remaining teeth may show. Our study also supports these findings, as it was apparent in our study that the eruption of the permanent teeth in the affected individuals is delayed (Fig 1 and 2). Numerous transcription factors, growth factors, and their receptors as well as structural molecules of the cell surface and extracellular matrix have been associated with early tooth morphogenesis (Nieminen, 2009; Thesleff, 2006). Interestingly, several of these genes have been shown to cause arrested tooth development and all these genes are also potential candidate genes for hypodontia (Matalova *et al.*, 2008; Pemberton *et al.*, 2005).

### Conclusion

As a conclusion, we identified a missense substitution (p.Ala240Pro) in two different Pakistani families with hypodontia and cleft lip palate.

### Acknowledgments

We are thankful to the families for their cooperation and participation in the study.

### References

**Arte S, Nieminen P, Apajalahti S, Haavikko K Thesleff I, Pirinen S.** 2001. Characteristics of incisor-premolar hypodontia in families. *Journal of dental research* **80(5)**, 1445-1450.

**Boyadjiev S, Jabs E.** 2000. Online Mendelian Inheritance in Man (OMIM) as a knowledgebase for human developmental disorders. *Clinical genetics* **57(4)**, 253-266.

**Cobourne M.** 2007. Familial human hypodontia—is it all in the genes? *British dental journal* **203(4)**, 203-208.

**Gorlin RJ, Cohen MM, Hennekam RC.** 1990. *Syndromes of the head and neck* Vol. **819**, Oxford University Press New York.

**Matalova E, Fleischmannova J, Sharpe P, Tucker A.** 2008. Tooth agenesis: from molecular genetics to molecular dentistry. *Journal of dental research* **87(7)**, 617-623.

**McKeown H, Robinson D, Elcock C, Al-Sharood M, Brook A.** 2002. Tooth dimensions in hypodontia patients, their unaffected relatives and a control group measured by a new image analysis system. *European Journal of Orthodontics* **24(2)**, 131-142.

**Mostowska A, Biedziak B, Zadurska M, Matuszewska-Trojan S, Jagodziński PP.** 2015. WNT10A coding variants and maxillary lateral incisor agenesis with associated dental anomalies. *European Journal of Oral Sciences* **123(1)**, 1-8.

**Nieminen P.** 2009. Genetic basis of tooth agenesis. *Journal of Experimental Zoology Part B: Molecular and Developmental Evolution* **312(4)**, 320-342.

**Pemberton TJ, Das P, Patel PI.** 2005. Hypodontia: genetics and future perspectives. *Braz J Oral Sci* **4(13)**, 695-706.

**Swartz ME, Sheehan-Rooney K, Dixon MJ, Eberhart JK.** 2011. Examination of a palatogenic gene program in zebrafish. *Developmental Dynamics* **240(9)**, 2204-2220.

**Thesleff I.** 2006. The genetic basis of tooth development and dental defects. *American Journal of Medical Genetics Part A* **140(23)**, 2530-2535.

**Vani NV, Saleh SM, Tubaigy FM, Idris A.** 2016. Prevalence of developmental dental anomalies among adult population of Jazan, Saudi Arabia. *The Saudi Journal for Dental Research* **7(1)**, 29-33.

**Zhou J, Gao Y, Lan Y, Jia S, Jiang R.** 2013. Pax9 regulates a molecular network involving Bmp4, Fgf10, Shh signaling and the Osr2 transcription factor to control palate morphogenesis. *Development* **140(23)**, 4709-4718.