



Protective effect of *Asparagus adscendens* on 5-fluorouracil induced gastrointestinal lesions in Wistar rats

Diksha Khajuria¹, Nawab Nashiruddullah², Nrip Kishore Pankaj², Raja A.H Kuchay¹, Jafrin Ara Ahmed², Syedah Asma Andrabi², Dibyendu Chakraborty², A.A. Shah*¹

¹Baba Ghulam Shah Badshah University, Rajouri

²Faculty of Veterinary Sciences & Animal Husbandry, Sher-e-Kashmir University of Agriculture Sciences and Technology, Jammu, Ranbir Singh Pura- 181102, UT of Jammu & Kashmir, India

Key Words: 5-Fluorouracil, *Asparagus Adscendens*, Gastrointestinal Lesions, Histopathology, Rats

<http://dx.doi.org/10.12692/ijb/24.5.117-125>

Article published on May 05, 2024

Abstract

The use of the anti-cancer drug 5-fluorouracil (5-FU) is known to induce intestinal mucositis in patients without known satisfactory preventive therapy. An ethanolic extract of *Asparagus adscendens* (A. a. EE) of was prepared with extractability percentage calculated as 27.2% (w/w) and a simple solution was made using CMC (carboxy methyl cellulose). Twenty-four five-week-old male Wistar rats were divided in four groups- Group-I acted as control (receiving oral saline), Group-II receiving 5-FU, Group-III receiving 5-FU and *Asparagus adscendens* EE, and lastly Group-IV receiving *Asparagus adscendens* EE alone. Dosage of *Asparagus adscendens* EE (300mg/kg body weight) was prepared in three divided doses and administered by gavage to the rats. A single intraperitoneal dose of 5-FU (500 g/ml) was injected in the test groups II and III. A drastic and significant ($p < 0.01$) fall in body weight between Group-II and III rats, together with severe diarrhoea score in these groups was noted. The histopathological scores derived from 11 devised parameters showed a severe and significant ($p < 0.01$) affliction of the ileum as compared to the jejunum in Groups-II and III. With 5-FU administration, histopathological changes in the jejunum were associated with severe pathology, such as- villi shortening, disruption of tips, degenerate enterocytes, Goblet cell reduction, marked mucosal mononuclear cell infiltration, significant loss of crypts or their distortion/loss, congestion of blood vessels and submucosal oedema. Similar changes also appeared in the ileum, together with lacteal dilation and hyperplastic Peyer's patches. In Group-III, enteric changes in the jejunum and ileum were indicative of mild enteritis, although far less in severity than observed in Group-II. In Group-IV changes were normal except for abundant Goblet cells, both in the jejunum and ileum. Overall *Asparagus adscendens* was found to significantly improve the detrimental effects induced by 5-FU.

* Corresponding Author: A.A. Shah ✉

Introduction

Chemotherapeutic drugs are known to cause many deleterious effects on patients diagnosed for cancer, and the term 'mucositis' is used to describe damage to mucous membranes after such medication (Sonis, 1993). Intestinal mucositis may be associated with severe diarrhoea and dehydration (Anilkumar *et al.*, 1992). In fact, chemotherapy frequently results in villous blunting and damaged crypts in the small intestine, mostly as a result of an increase in apoptosis, and a decrease in mucosal proliferation (Vanhoecke *et al.*, 2015). This complication is frequently associated with the use of 5-Fluorouracil (5-FU) in the treatment of several malignant cancers, including those in the alimentary system.

5-FU is a fluoropyrimidine that principally acts as a thymidylate synthase (TS) inhibitor preventing DNA replication, and proves cytotoxic to cancer cells. But it is also known to cause direct toxicity, oxidative stress, apoptosis, hypo-proliferation and inflammation (Daniele *et al.*, 2001; Sonis, 2004), leading to intestinal mucositis, alongside other side effects. Active metabolites of 5-FU, such as 5-fluoro-2'-deoxyuridine-5'-monophosphate, 5-fluorouridine-5'-triphosphate and 5-fluoro-2'-deoxyuridine-5'-triphosphate, inhibit thymidylate synthase, DNA and RNA synthesis which is essential for cellular homeostasis and survival (Longley *et al.*, 2003). It is intricately associated with direct cell damage by generation of reactive oxygen species, activation of different transcription pathways, up-regulation of inflammatory mediators like NF- κ B, COX-2, i-NOS, proinflammatory cytokines, IL-4, all precipitating in inflammation, neutrophilic infiltration and ulceration of the intestinal mucosa (Sonis *et al.*, 2004, Soares *et al.*, 2013).

Presence of apoptotic cells in intestinal crypts causing mucosal destruction suggests an important pathogenic mechanism of 5-FU-induced intestinal mucositis (Anil kumar *et al.*, 1992, Pritchard *et al.*, 1998, Yasuda *et al.*, 2012). However, unlike other systemic complications, there is no prevention or effective treatment for intestinal mucositis (Soinis,

2004), thus limiting effective chemotherapy (Kato *et al.*, 2015). Despite its negative effects on patients, the quest for new therapeutic targets however cannot be thwarted, and alternative answers may be sought from herbal medicines. The use of herbal drugs with lesser side effects has recently found interest in modern research and pharmacognostic evaluations. This is imperative in chemotherapeutic use of compounds that are associated with deleterious side effects. Alkaloids, terpenoids, and secondary metabolites are frequently present in plants as herbal alternatives, and can help with mucosal healing without harming other cells. There can be increasing possibilities of such herbal supplements for human and animal health, particularly in terms of enhancing intestinal function.

A perusal of literature and knowledge of local ethnobotany directed our attention to the herb *Asparagus adscendens* as a promising candidate for attenuating mucositis. The beneficial effects of *A. a.* for maintaining gastrointestinal epithelium homeostasis, prevention of chronic gastritis, attenuation of diarrhoea (Dixit and Mittal, 2013), ameliorating chemotherapeutic mucositis with intestinal damage (Kumar *et al.*, 2022), and alleviating colitis symptoms (Ahmed *et al.*, 2021) have been engrossing. Belonging to class Liliaceae, *Asparagus adscendens* (*A.a.*) is a plant commonly found in South Asian countries. Commonly known as 'safedmusli' or 'shwetamusli', they grow wild in Jammu & Kashmir (Saran *et al.*, 2020) alongside another related species- *Asparagus racemosus* commonly known as 'shatavari'. Medicinal properties of these plants have been long known and documented since ancient times. Progressive research on *Asparagus* roots have found various bioactive compounds, such as polyphenols, flavonoids, steroidal saponins (Shatavarin I-IV), minerals and alkaloid components (asparagamine and racemosol) (Saxena and Chourasia, 2001; Palanisamy and Manian, 2012). *Asparagus racemosus* also finds mention in Indian and British pharmacopoeias (Mishra and Verma, 2017) for their therapeutic properties; however, the composition profiles are

invariably affected by its botanical and geographical origins (Gouet *et al.*, 2023). The literature abounds in research highlighting the phytoestrogenic, anti-oxidant, immune-modulator, anti-inflammatory, anti-infertility, anti-cancer, cardio-protective properties, etc. (Bansode *et al.*, 2015; Mishra and Verma, 2017; Saran *et al.*, 2021) apart from its pivotal role in treating alimentary ailments.

However, as far as we are aware, the use of *Asparagus adscendens* and its amelioration of intestinal mucositis brought on by 5-fluorouracil has not yet been detailed. It was hypothesized that *A. a.* could maintain mucosal integrity otherwise disrupted by 5-FU. To ascertain its muco-protective role, the current investigation was carried out with an *A. a.* extract after a single intra-peritoneal dose of 5-FU in a rat model, while monitoring gastrointestinal morphological changes and semi-quantitative assessment of lesions.

Materials and methods

Animal ethical clearance

The study was conducted in accordance with the ethical guidelines approved by the Institutional Animal Ethics Committee under approval no. 12/IAE/21/2023 of SKUAST-Jammu.

Preparation of ethanol extract

Fully developed dark brown roots of *Asparagus adscendens* were collected from the vicinity of the Biotechnology Department of Baba Ghulam Shah Badshah University, Rajouri in the month of June 2021. Plant species were recognized by descriptive and identifying characteristics. The plant roots were collected from their natural habitat, carefully cleansed with tap water and then with distilled water, and were allowed to dry for 20 days in the shade. An electric blender was used to powder the dried roots and sieved through a household strainer to obtain a fine powder. Extraction was carried out in conical flasks with 20 grams of powdered plant material and 100 mL of ethanol or another solvent introduced one at a time. Aluminum foil was placed over the flask's mouth and shaken continuously for 24

hours at a speed of 150 revolutions per minute to thoroughly mix the ingredients and fully reveal the active ingredients in each solvent. The extract was then filtered through muslin cloth and filter paper (Whatman no. 1). Subsequently, the extract was obtained using a rotating vacuum evaporator in a 50°C water bath (Auniqet *et al.*, 2021), and stored 4°C in a refrigerator until further use. The color of the extract was dark brown, crystal-like and semi-solid in texture. Extractability percentage of *Asparagus adscendens* ethanol extract (*A. a.* EE) of was calculated as 27.2% (w/w) using the formula-

$$\text{Percent extractability} = \frac{\text{Weight of extract obtained}}{\text{weight of plant material taken for extraction}} \times 100$$

Administration of extract

A simple solution was made from the extract using CMC (carboxy methyl cellulose) for oral administration in experimental rats (0.6 g of *A. a.* EE was dissolved in 0.1 g CMC and 10 ml distilled water) and calibrated to a final dose of 300 mg/kg body weight that was fed by gavage to the treatment groups. Dosage was prepared for 3 days and stored in refrigerator at 4°C. Regular monitoring was carried out for any change in color or texture.

Induction of intestinal mucositis with 5-FU

A single dose of 5-Fluorouracil @150 mg/kg body weight (Logan *et al.*, 2009) was administered by intra-peritoneal injection in rats of the test groups.

Experimental animals

Twenty-four five-week old male Wistar rats weighing (146-165 g) were acquired from the Indian Institute of Integrated Medicine (IIIM), Jammu and acclimatized for 2 weeks before start of experiment in the Division of Pharmacology and Toxicology, SKUAST-Jammu. The animals were treated with anthelmintic Albendazole oral suspension @15 mg/kg single dose (Albomar, Virbac, India), and housed in a controlled environment (23°C, relative humidity of 50-55%, with a 12 hour light/dark cycle) with access to *ad libitum* food and water. The animals were randomly divided into four groups of six rats each, *viz.* Group-I as negative control receiving oral saline, Group-II

receiving 5-FU, Group-III receiving 5-FU and *A. a.* EE, and lastly Group-IV receiving *A. a.* EE alone.

Experimental parameters

Multiple parameters (weight change, diarrhoea, inflammation, histopathology, etc.) of mucositis in the test groups were compared with the saline control group. Body weight and diarrhoea status were measured daily to determine the severity of the disease. Diarrhoea was rated according to stool consistency, with grades ranging from 0 (normal stool or absent) to 3 (severe, watery stool with significant perineal soiling).

The rats were euthanized under anaesthesia, and subjected to a thorough necropsy examination. The ileum and jejunum length were measured after removal and collected for further analysis.

Histopathology and analysis

Jejunum and ileal tissues preserved in 10% buffered formalin were processed, embedded in paraffin wax, sectioned at 4-5 μm slices, and stained with haematoxylin and eosin (H&E). Histopathological analysis was done based on criteria described by Howarth *et al.* (1996), to determine the severity of the intestinal lesions. Each intestinal segment (jejunum, and ileum) was evaluated using eleven histological parameters, and a semi-quantitative histological score with a possible maximum score of 33 points, that evaluated each parameter from normal (zero) to severe (three) depending on severity of lesions. The score card is detailed below-

Histopathological Parameter Score normal (0) to severe (3)

1. Villous fusion and stunting (atrophy):
2. Disruption of brush border and surface enterocytes:
3. Reduction in goblet cell number:
4. Reduction in numbers of mitotic figures:
5. Crypt loss/ architectural disruption:
6. Disruption or distortion of crypt cells:
7. Crypt abscess formation:
8. Infiltration by inflammatory cells:
9. Dilatation of lymphatics and capillaries:
10. Thickening, edema of the submucosa:
11. Thickening, edema of the muscularis externa layers:

Maximum score: 33

Statistical analysis

One way analysis of variance (ANOVA) was used (SPSS version 17.0) to analyze the difference in mean of data recorded and significance between mean values were determined by Duncan's Multiple Range Test (DMRT). Each sample was quantified in triplicate in order to maintain consistency.

Results

Observations in body weight changes and diarrhoea

Average body weight and diarrhoea score recorded was compared statistically and represented in Table 1. It was evident that there was drastic and highly significant ($p < 0.01$) fall in body weight between all groups except Group-III and IV rats. The difference in body weight (gain/loss) on day 4 is represented in Figure 1, which shows highly significant ($p < 0.01$) differences between all groups. It is clear that *Asparagus adscendens* could ameliorate body weight loss to some extent induced by 5-FU. However, animals also showed a very mild but non-significant decrease in weight when treated with *A. a.* alone (Group-IV). This was attributed to two rats with mild decrease in body weight (≤ 5.0 g), while a marginal decrease was shown in two other animals (≤ 1.0 g) within the short period of 4 days.

The diarrhoea score observed on day 4 is represented in Figure 2. Rats treated with 5-FU showed severe diarrhoea that was highly significant ($p < 0.01$) between Groups-II and III, and also compared to either control or Group IV animals. *A. a.* seemingly showed significant improvement in diarrhoea in rats of Group-III. Two rats in Group-IV showed very mild loose faeces that attributed to a marginal diarrhoeic score.

Histological observations

The histopathological scores in the jejunum and ileum are depicted in Table 2 and Figure 3 and descriptive pathological changes are depicted in Figure 4. The histopathological scores derived from 11 devised parameters showed a severe and highly significant ($p < 0.01$) affliction of the ileum as compared to the jejunum in Groups-II and III.

The severity was maximum in the group treated with 5-FU alone, while incorporation of *Asparagus adscendens* in Group-III rats showed significant amelioration of the histopathological indices. The descriptive pathology of jejunum and ileum are detailed below-

Group 1 (control)

The histological features of the jejunum and ileum were unremarkable, showing normal mucosa, villi features and crypt morphology. Peyer's patches in the ileum also appeared normal.

Group II (5-FU)

Changes in the jejunum and ileum were associated typically with severe pathology. Jejunal villi were shortened; tips appeared disrupted, with some degenerate surface enterocytes. Goblet cells were markedly decreased in abundance. There was marked mononuclear cell infiltration within the lamina propria of the mucosa. There appeared a significant loss of crypts; those present appeared distorted, with reduction of crypt cells. Mild congestion of blood vessels was seen with considerable oedema in the submucosa.

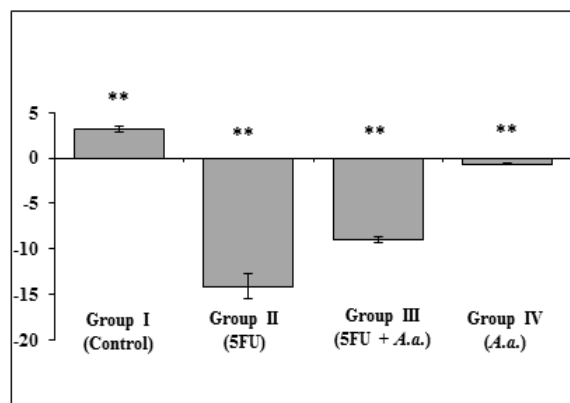


Fig. 1. Difference in body weight (Mean ± SE) after 5-Fluorouracil (5-FU) and *Asparagus adscendens* (A. a) administration in different groups of Wistar rats.

Ileal villi tips also appeared blunted and disrupted. Some enterocytes appeared degenerated, while others appear swollen with a vesiculated cytoplasm. Goblet cells were significantly reduced in abundance. Villi were marked with significant inflammatory cellular infiltration mostly composed of polymorphonuclear cells, lymphocytes and some macrophages. Blood

vessels were severely dilated with considerable oedema in the mucosa. The lacteals appear dilated and Peyer's patches were hyperplastic. Some lymphocytic infiltration could also be seen within the lacteals.

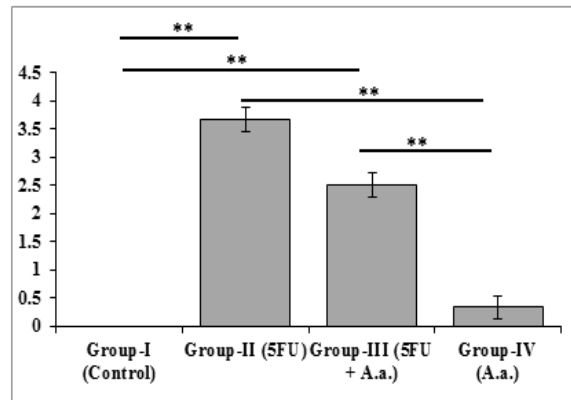


Fig. 2. Diarrhoea score (Mean ± SD) after 5-Fluorouracil (5-FU) and *Asparagus adscendens* (A. a) administration in different groups of Wistar rats.

Group-III (5-FU + A. a.)

Enteric changes in the jejunum and ileum were indicative of mild enteritis, although less in severity than observed in group-II. Jejunum showed some disrupted villi tips with mild blunting. Goblet cells were less. Epithelial cells of the mucosal lining as well as the crypt cells appeared swollen with a vesiculated cytoplasm. Villi appear oedematous with scanty inflammatory cellular infiltration. Ileum also showed disrupted villi tips, while blood vessels appeared congested. The mucosa appeared oedematous. Villi were marked with few cellular infiltrations. The lacteals appear dilated and Peyer's patches were hyperplastic.

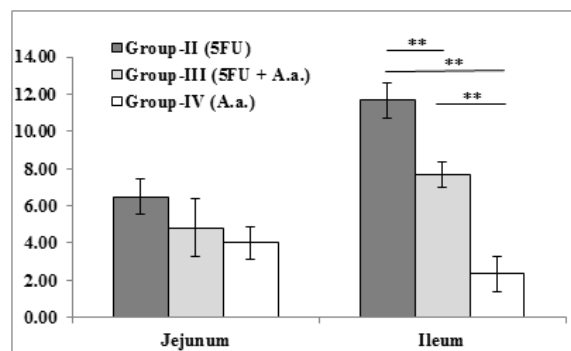


Fig. 3. Histopathological score (Mean ± SE) of jejunum and ileum in Wistar rats after administration of 5-Fluorouracil (5FU) and *Asparagus adscendens* alone, and in combination.

Group-IV (A. a.): histopathological changes appeared near normal. There were abundant goblet cells, both in the jejunum and ileum. Jejunum revealed a normal villi structure, and the mucosal features were akin in the ileum too. Ileal Peyer's patches appeared normal.

Discussion

The changes seen in 5-FU induced gastrointestinal pathology in the rat jejunum were similar to the description by Logan *et al.* (2009). The current study

shows that *Asparagus adscendens* supplementation appreciably mitigates the entero-cytotoxic effects of 5-FU. This has been documented in a mild, but discernible mitigation of clinical signs such as diarrhoea and the subsequent body weight loss.

Further, its protective effect on the enteric histology is apparent from a considerable improvement and amelioration of an otherwise severe enteropathy observed with 5-FU treatment alone.

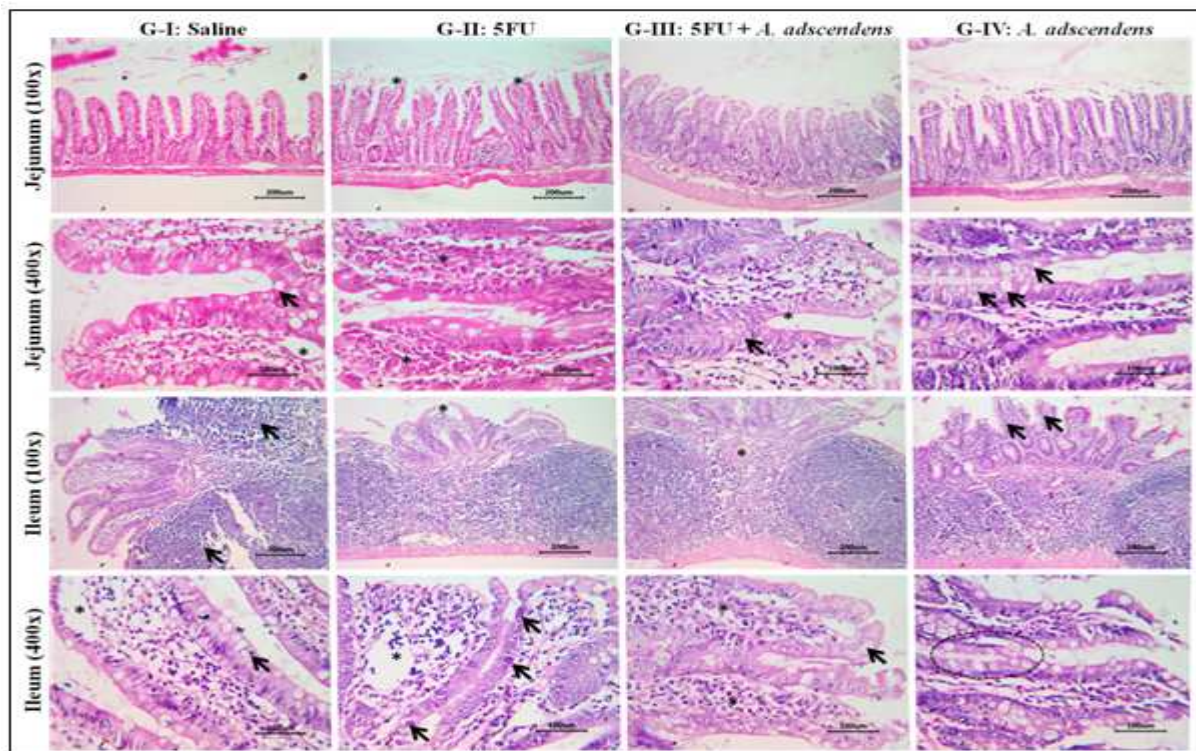


Fig. 4. Histopathological changes in Wistar rat jejunum and ileal mucosa in control (G-I: Saline) and treatment groups (G-II: 5FU; G-III: 5FU + *A. adscendens*; G-IV: *A. adscendens*)

- Jejunum, 100x (L-R): Normal mucosa; Disruption of the villi tips (*); Moderate disruption of villi tips; Mucosa with mild goblet cell hyperplasia
- Jejunum, 400x (L-R): Higher magnification of normal mucosal villi showing goblet cells (arrow) and lacteals (*); Villi showing severe infiltration by mononuclear cells (*); Villi showing oedema and swollen epithelial cells of glandular (arrow) and lining mucosa (*) with cytoplasmic vesiculation; Villi showing goblet cell hyperplasia (arrows).

Specifically, the degree of enteritis was reduced by visible alleviation of villi disruption, and a perceivably less cellular infiltration. Both observable improvements in enteric signs and lesions have been corroborated by a highly significant statistical result in the 5-FU treatment groups, *viz.* between treatment with 5-FU alone, and 5-FU supplemented with

Asparagus adscendens. It however does not bring about a complete attenuation of lesions. The reason for a partially efficacious result is open to speculation. There could be many factors that need to be addressed. First, the ethanolic extract of the herbal product is a crude mixture of many compounds whose concentration of active principles could vary

with herbage; while the second most important consideration is the concentration and duration of *A. a.* treatment. As in the present study, administration of *Asparagus adscendens* was only for a short duration of 3 days, it is conjectured that an extended treatment could have been more effective.

In an experiment, Singh *et al.* (2011) had used *A. a.* in a dietary concentration of 2, 4, and 6% (w/w) as pelleted feed for prolonged periods ranging from 120-180 days to successfully demonstrate its chemomodulatory potential in a mice model. Dose dependent effects of *A. a.* have also been verified while evaluation its anabolic, reproductive, and sexual behavioral activity in rats orally fed with ethanolic extract at 100, 200, and 300 mg/kg body weight for 30 days (Bansode *et al.*, 2015), and so does *Asparagus racemosus* (Sairam *et al.*, 2003). It would therefore be tempting to suggest a longer period of *Asparagus adscendens* therapy to achieve better results.

Asparagus adscendens has antioxidant potential (Singh *et al.*, 2011) and anti-inflammatory properties through mediation of many of its active compounds like diosgenin (Khan *et al.*, 2017) and sapogenin (Sharma *et al.*, 1982), to name a few. It has been reported that *A. adscendens* enhances the specific activities of SOD, catalase, glyoxalase-I as well as levels of GSH in the liver and other tissues, whereas there is a concurrent decrease in LDH activity and measureable oxidative damage to prove its antioxidant efficacy (Singh *et al.*, 2011). Since intestinal mucositis is largely mediated by oxidative injury through generation of ROS, it is hypothesized that *A. a.* could in part scavenge these free radicals and impart protection against entero-mucosal damage.

Conclusion

It was interesting to note that in rats administered with *Asparagus adscendens* alone, the mucus activity and proliferation of Goblet cells had increased. There have been reports of *Asparagus racemosus* increasing secretion and viscosity of gastrointestinal

mucus (Singh and Singh, 1986; Mangal *et al.*, 2006; Bhatnagar and Sisodia, 2006) and significantly increases the glycoprotein content of mucosal cells (Sairam *et al.*, 2003). Since there were no untoward clinical or histological effects of feeding *Asparagus adscendens* in the rats, it can be presumed that its incorporation as a regular supplement can be safe.

The present results show that the herbal extract of *Asparagus adscendens* is partially effective to mitigate signs of diarrhea, weight loss, and histopathological lesions typically associated with 5-fluorouracil administration. It is speculated that a protracted treatment with *Asparagus adscendens* could give better results, since it has been often documented that its effects are dose dependant. However, a dose dependant study is warranted together with evaluation of other marker parameters of *Asparagus adscendens* supplementation as a safe alternate therapy of chemotherapy induced intestinal mucositis in human patients.

References

- Ahmed SR, Rabbee MF, Roy A, Chowdhury R, Banik A, Kubra K, Hassan Chowdhury MM, Baek KH. 2021. Therapeutic promises of medicinal plants in Bangladesh and their bioactive compounds against ulcers and inflammatory diseases. *Plants*, **10**(7), 1348.
- Anilkumar TV, Sarraf CE, Hunt T, Alison MR. 1992. The nature of cytotoxic drug-induced cell death in murine intestinal crypts. *British Journal Cancer*, **65**, 552-558.
- Aunig RB, Chy MN, Adnan M, Chowdhury MR, Dutta T, Ibban SS, Jahan I, Tona MR, Shima M, Sawon MI, Chakrabarty N. 2021. Evaluation of anxiolytic, sedative, and antioxidant activities of *Vitexpeduncularis* Wall. leaves and investigation of possible lead compounds through molecular docking study. *Advances in Traditional Medicine* **21**, 507-518.
- Bansode FW, Arya KR, Singh RK, Narender T. 2015. Dose-dependent effects of *Asparagus adscendens* root (AARR) extract on the anabolic, reproductive, and sexual behavioral activity in rats. *Pharmaceutical Biology* **53**(2), 192-200.

- Bhatnagar M, Sisodia SS.** 2006. Antisecretory and antiulcer activity of *Asparagus racemosus* Willd. against indomethacin plus pyloric ligation-induced gastric ulcer in rats. *Journal of Herbal Pharmacotherapy* **6(1)**, 13–20.
- Daniele B, Secondulfo M, De Vivo R, Pignata S, De Magistris L, Delrio O, Barletta E, Tambaro R, Carratu R.** 2001. Effect of chemotherapy with 5-fluorouracil on intestinal permeability and absorption in patients with advanced colorectal cancer. *Journal of Clinical Gastroenterology* **32**, 228–230.
- Dixit PK, Mittal S.** 2013. Comparative haematological study of ethanolic and hydroalcoholic extract of *Asparagus racemosus* roots by FCA induced arthritis in rats. *World Journal of Pharmaceutical Research* **2(3)**, 693-698.
- Gou H, Gu LY, Shang BZ, Xiong Y, Wang C.** 2016. Protective effect of Bu-Zhong-Yi-Qi decoction, the water extract of Chinese traditional herbal medicine, on 5-fluorouracil-induced intestinal mucositis in mice. *Human and Experimental Toxicology* **35(12)**, 1243-1251.
- Howarth GS, Francis GL, Cool JC, Xu X, Byard RW, Read LC.** 1996. Milk growth factors enriched from cheese whey ameliorate intestinal damage by methotrexate when administered orally to rats. *Journal of Nutrition* **126**, 2519-2530.
- Kato S, Hayashi S, Kitahara Y, Nagasawa K, Aono H, Shibata J, Utsumi D, Amagase K, Kadowaki M.** 2015. Saireito (TJ-114), a Japanese traditional herbal medicine, reduces 5-fluorouracil-induced intestinal mucositis in mice by inhibiting cytokine-mediated apoptosis in intestinal crypt cells. *PLoS One* **10(1)**, e0116213.
- Khan KM, Nahar L, Mannan A, Arfan M, Khan GA, Al-Groshi A, Evans A, Dempster NM, Ismail FM, Sarker SD.** 2017. Liquid chromatography mass spectrometry analysis and cytotoxicity of *Asparagus adscendens* roots against human cancer cell lines. *Pharmacognosy Magazine*, **13(4)**, S890.
- Kumar P, Rai S, Verma SK, Prakash PS, Chitara D.** 2022. Classification, Mode of Action and Uses of Various Immunomodulators. In: Kesharwani, R.K., Keservani, R.K., Sharma, A.K. (eds) *Immunomodulators and Human Health*. Springer, Singapore p 3-38.
- Logan R, Stringer A, Bowen J, Gibson R, Sonis S, Keefe D.** 2009. Is the pathobiology of chemotherapy-induced alimentary tract mucositis influenced by the type of mucotoxic drug administered? *Cancer Chemotherapy and Pharmacology* **63**, 239–251.
- Longley B, Harkin DP, Johnston PG.** 2003. 5-fluorouracil: mechanisms of action and clinical strategies. *Nature Reviews Cancer* **3**, 330–338.
- Mangal A, Panda D, Sharma MC.** 2006. Peptic ulcer healing properties of Shatavari (*Asparagus racemosus* Wild.). *Indian Journal of Traditional Knowledge* **5(2)**, 227-228.
- Mishra JN, Verma NV.** 2017. *Asparagus racemosus*: chemical constituents and pharmacological activities- a review. *European Journal of Biomedical and Pharmaceutical Sciences*, **4(6)**, 207-213.
- Palanisamy N, Manian S.** 2012. Protective effects of *Asparagus racemosus* on oxidative damage in isoniazid-induced hepatotoxic rats: an in vivo study. *Toxicology and Industrial Health* **28(3)**, 238–244.
- Pritchard DM, Potten CS, Hickman JA.** 1998. The relationships between p53-dependent apoptosis, inhibition of proliferation, and 5-fluorouracil-induced histopathology in murine intestinal epithelia. *Cancer Research* **58**, 5453–5465.
- Sairam K, Priyambada S, Aryya NC, Goel RK.** 2003. Gastroduodenal ulcer protective activity of *Asparagus racemosus*: an experimental, biochemical and histological study. *Journal of Ethnopharmacology* **86(1)**, 1–10.

- Saran PL, Singh S, Solanki V, Choudhary R, Manivel P.** 2021. Evaluation of *Asparagus adscendens* accessions for root yield and shatavarin IV content in India.
- Saxena VK, Chourasia S.** 2001. A new isoflavone from the roots of *Asparagus racemosus*, *Fitoterapia*, **72(3)**, 307–309.
- Sharma S, Chand R, Sati OP.** 1982. Steroidal Sapogenins of *Asparagus adscendens*. *Phytochemistry* **21(8)**, 2075–2078.
- Singh KP, Singh RH.** 1986. Clinical trial on Shatavari (*Asparagus racemosus* Willd) on duodenal ulcer disease. *Journal of Research in Ayurveda and Siddha* **7**, 91–100.
- Singh M, Shrivastava D, Kale RK.** 2011. Chemomodulatory potential of *Asparagus adscendens* against murine skin and forestomach papillomagenesis. *European Journal of Cancer Prevention* **20**, 240–247.
- Soares PMG, Mota JM, Souza EP, Justino PFC, Franco AX, Cunha FQ, Ribeiro RA, Souza MHL.** 2013. Inflammatory intestinal damage induced by 5-fluorouracil requires IL-4. *Cytokine*, **61(1)**, 46–49.
- Sonis ST.** 1993. Complications of cancer and their treatment: oral complications. In: Holland, J.F., Frei, E., Bast, R.C., Kufe, D.W., Morton, D.L., Weichselbaum, R.R. (eds). *Cancer Medicine* (3rd edition). London: Lea and Febiger. 2381–2388 p.
- Sonis ST.** 2004. The pathobiology of mucositis. *Nature Reviews Cancer* **4(4)**, 277–284.
- Sonis ST, Elting LS, Keefe D, Peterson DE, Schubert M, Hauer–Jensen M, Bekele BN, Raber-Durlacher J, Rubenstein EB.** 2004. Perspectives on cancer therapy–induced mucosal injury. *Cancer* **100(S9)**, 1995–2025.
- Vanhoecke B, Bateman E, Mayo B, Vanlancker E, Stringer A, Thorpe D, Keefe D.** 2015. Dark Agouti rat model of chemotherapy-induced mucositis: establishment and current state of the art. *Experimental Biology and Medicine* **240(6)**, 725–741.
- Yasuda M, Kato S, Yamanaka N, Iimori M, Matsumoto K, Utsumi D, Kitahara Y, Amagase K, Horie S, Takeuchi K.** 2013. 5-HT₃ receptor antagonists ameliorate 5-fluorouracil-induced intestinal mucositis by suppression of apoptosis in murine intestinal crypt cells. *British Journal of Pharmacology* **168(6)**, 1388–140.