



RESEARCH PAPER

OPEN ACCESS

Studying the effects of erythropoietin in the prevention of liver inflammation and subsequent cell death induced by ischemia-reperfusion in rats

Seyyed Saied Disnad, Yousef Doustar*

Department of Pathobiology, Tabriz Branch, Islamic Azad University, Tabriz, Iran

Key words: Liver Ischemic reperfusion, erythropoietin, cell death.

<http://dx.doi.org/10.12692/ijb/6.2.76-83>

Article published on January 18, 2015

Abstract

EPO is a cytokine that was originally identified as the major regulator of erythroid precursor cells. However EPO attenuates cell damage and inflammatory reactions. In the present study, we examined the effect of EPO on liver ischemic reperfusion injury and also on the occurrence of cell death and inflammatory response in an *in vivo* rat model of liver I/R injury. Studies were performed on male wistar rats weighing 200 to 250 g ($n = 8$). Rats received a standard diet and water ad libitum and were housed in a 12-h light/dark cycle. The animals were randomly allocated into two groups: (1) I/R-saline group, in which rats were subjected to renal ischemia for 30 min ($n = 8$); (2) I/R-EPO group, in which rats were administered EPO (500 U/kg, i.p.) 60 min prior to I/R ($n = 8$) in which rats were subjected to identical surgical procedure without occlusion of both portal and liver artery pedicles and maintained under anesthesia for the duration of the experiment ($n = 8$). In group 2 erythropoietin caused significant decrease cell death and inflammatory reactions in comparison with control group ($p < 0.001$). Results indicated that erythropoietin inhibits cell death and inflammatory reactions in the liver rats.

*Corresponding Author: Yousef Doustar ✉ doustar@iaut.ac.ir

Introduction

Ischemic liver failure occurs following the discontinuation or reduction of blood flow to the liver. Despite preventive and therapeutic proceedings, the disease is still associated with a high mortality rate (Barr and Tomei, 1994).

Tissue damage starts from ischemic phase. Necrosis and apoptosis are two forms of cell injury; the cell contents egress in necrosis and damage the adjacent tissues. During apoptosis, which is a scheduled death, nuclear and cytoplasm elements perch within apoptotic vacuoles and then ingested by macrophages without any damage to the adjacent tissues (Barr and Tomei, 1994- Bramey *et al.*, 2009).

Blood returning following the primary phase of ischemic causes new damages in the organ; so, the two phases is called ischemic reperfusion (IR) (Bramey *et al.*, 2009). New findings in this area have focused on the role of inflammation in the pathogenesis of ischemic reperfusion (Barr and Tomei, 1994- Bramey *et al.*, 2009). Several inflammatory mediators released in the ischemic, of which the most important are: tumor necrosis factor alpha (TNF- α), interleukin-1 (IL-1), interleukin-6 (IL-6), interleukin-8 (IL-8) and etc. The mediators cause to occur and expand the inflammation in the reperfusion phase. With increased intercellular adhesion molecule-1 (ICAM-1) on the surface of endothelial cells pull off multi-core cells into ischemic tissue. Entering the Polymorphonuclear inflammatory leukocytes (PMN) in the tissue is concurrent with Myeloperoxidase (MPO) enzyme and consequently the combination of nitric oxide (NO) with super oxide radicals and the production of Peroxynitrite (ONOO) induces oxidative stress in the inflammatory process which increases the extent of ischemic damage. The mentioned process demonstrates the central damaging-role of inflammation following ischemic reperfusion (Barr and Tomei, 1994- Elmore, 2007).

Erythropoietin (EPO) which is a cytokine, has been known as a Hematopoietic hormone. Its effective

mechanism is the reduction of apoptosis of Erythroblast in the marrow. Its synthesized form is also available and is used in abundance to remove anemia in patients with chronic renal failure (Fadeel and Orrenius, 2005- Franklin *et al.*, 2006- Han *et al.*, 2008). The recent views on EPO suggest its anti-apoptotic effects on liver, nervous system and heart damages. EPO in liver cells inhibits apoptosis by nuclear factor kappa-light-chain-enhancer of activated B cells (NF- κ B). It seems that the process occurs by increased anti-apoptotic factors such as BCL-2, BCL-XL, XIAP, (Hsp70s) that inhibits apoptosis through the mitochondrial membrane consolidation and preventing the entrance of cytochrome C into the cytoplasm and inhibit caspase triggering apoptosis (Eipel *et al.*, 2012- Fadeel and Orrenius, 2005- Franklin *et al.*, 2006- Han *et al.*, 2008). Furthermore, EPO reduces the coagulation in the blood vessels of the ischemic organs by reducing expression of Phosphatidylserine (PS) on endothelial surface (Barr and Tomei, 1994- Eipel *et al.*, 2012).

Another interesting point is that by increasing the presence of Major histocompatibility complex 2 (MHC2) and Toll Like Receptor (TLR) in the liver cells and liver vessel endothelial, causing the increased inflammation and immunogenicity in liver (Hetz, 2008- Joyeux-Faure, 2007). It seems that there is a relationship between apoptosis inhibition and inflammation. On the other hand, caspase causing apoptosis can induce the increased release of inflammatory mediators; therefore, increased infiltration of PMN in ischemic organ.

It seems that the process occurs due to increased ICAM-1 at the endothelial level of ischemic organ vessels (Hetz, 2008- Joyeux-Faure, 2007). Recent studies on animals and cell cultures have demonstrated that EPO has anti apoptotic effects (Hetz, 2008- Joyeux-Faure, 2007). Anti-apoptosis effects of EPO and its protective role against ischemic damages has been a new area of the studies conducted in recent years.

In the present study, we examined the effect of EPO

on liver ischemic reperfusion injury and also on the occurrence of cell death and inflammatory response in an *in vivo* rat model of liver I/R injury.

Materials and methods

Animals

Sixteen male Wistar rats weighing 200-250 g were divided into two groups of 8 rats and they were randomly divided into two groups: 1- The control group with closed vascular pedicles, 2- The treatment group, treated with erythropoietin due to ischemia-reperfusion

Nutrition

Water and food intake as well as body weight were measured and symptoms such as Tachypnea and dyspnea were evaluated in terms of incidence and severity. In the treatment group, 500 IU/Kg EPO was injected intraperitoneally one hour before ischemia induction.

Anesthesia

The groups were not given food at all for 2 hours and ketamine (10%) 50 mg/kg and xylazine (2%) in the amount of 5 mg/kg using a needle with a 25 gage, intraperitoneal injection was used in order to anesthesia.

Surgery

Then, the anesthetized animal's abdomen was shaved and sterilized with 70% ethanol or Betadine solution to prepare for surgery. A pair of small scissors was used to open the abdomen from its middle line and cut the abdominal contents.

The 3 cm-cutting was started from the middle of the abdomen and ended in sternum. The cutting was not extended from the sternum area because of large intra-cutaneous vessels and muscular layers cause hemorrhage. To see the vein and its associated structures, the intestine was removed carefully from abdominal cavity using two wet cotton swabs and placed on wet tampon (soaked in normal saline 9%). The intestines were covered with another tampon in order to prevent becoming dry. To better view of the

triad set of portals (portal vein, hepatic artery, bile duct) the fourth liver lobe was separated from left lateral lobes carefully using carefully scissors. Then, an Atromatic forceps were used at the top of one of the right lateral branches to block the portal vein, hepatic artery and bile duct.

The right and middle left side lobes (approximately 70% of the liver), showed an immediate pallor. They must have changed immediately the reddish brown color to the normal brown or cream color. After placing the clamp, the intestines were placed again into the abdominal cavity, then 500 µl of 10 ml/U heparinized saline was directly injected into the peritoneal cavity and cutting area was covered carefully with salinized tampons. The Animal was monitored under a heat lamp to maintain body temperature at 37 °c during the ischemic period.

The covering Tampon was controlled in terms of its humidity. After the desired period of ischemia (30 minutes), the clamp was opened carefully and 500 µl of sterile saline was injected into the peritoneal cavity to replenish any lost fluids during surgery.

If the lobes paleness began to return to the normal color, reddish brown, within a few seconds, followed by the clamp removal, Reperfusion would be confirmed. Then, the abdominal cavity was closed by suturing the muscle layer and then suturing the skin with 0-4 silk sutures. The animals were allowed to be recovered and pass the 24 hours of reperfusion period.

Microscopic Pathology

Finally, the animals were euthanized and their liver was removed for microscopic studies. The livers were sent to the Veterinary Medicine pathology laboratory of the Tabriz Islamic Azad University, followed by stabilization in 10% buffered formalin. Successive 5 µ thickness slices of liver were prepared and stained normally. Pathological changes in the liver tissue were analyzed using optical microscopy.

Statistical Analysis

Quantitative Data were presented as mean \pm standard Deviation (mean \pm SD) and the significant differences between groups were analyzed using ANOVA and tukey tests. Differences in the level of $p < 0.05$ were considered significant.

Results

In the group treated with EPO, reduced cell damage, hemorrhage and inflammatory cell infiltration (Figures 3-12, 3-13) occurred; so, there was a

significant difference between this group (3.900 ± 0.5667) and ischemia-reperfusion group (11.300 ± 0.6155) ($p < 0.001$). However, the drug dose could not reach the cell death changes to a normal rate and still there was a significant difference between this group and the healthy control group (0.3333 ± 0.1667) ($p < 0.05$). Comparison of the mean and standard deviation of the treatment and control groups is shown in diagram 1.

Table 1.

Groups	Necrosis	Hemorrhage	Inflammatory Cell Infiltration
Control	o	o	o
IR	+++	++++	++++
ATOR+IR	++	++	++

Score Information: Normal and without of pathologic changes (o), Minimal pathologic changes (+), Moderately pathologic changes (++), severe pathologic changes (+++) and very severe pathologic changes (++++).

Discussion

It was revealed that administration of erythropoietin may improve liver ischemic injury followed by administration of cisplatin (Bramey *et al.*, 2009). In another study it was demonstrated that EPO can improve liver dysfunction resulted of endotoxaemia (Eipel *et al.*, 2012). Researchers demonstrated that EPO can have a protective role followed by liver transplantation (Barr and Tomei, 1994- Bramey *et al.*, 2009- Eipel *et al.*, 2012).

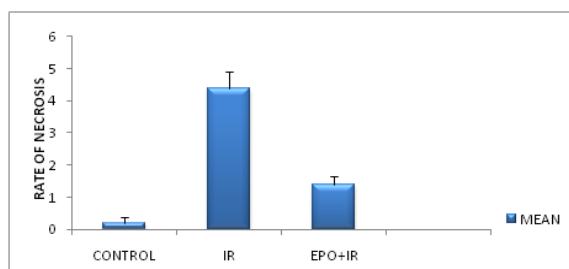


Fig. 1. Mean levels of cell death with necrosis of the liver in treatment and control group (n = 8). Data are shown as mean \pm SE.

The EPO is involved in a complex network of cytokines also plays an important role in the prevention of ischemic reperfusion injury. The hormone concentration in plasma is 1-26 mu/ml. It has been well known that EPO and its receptors have an important role in prenatal growing. Not only it has

an important role in RBC stimulation, but also has a fundamental role in the production and development of vascular system.

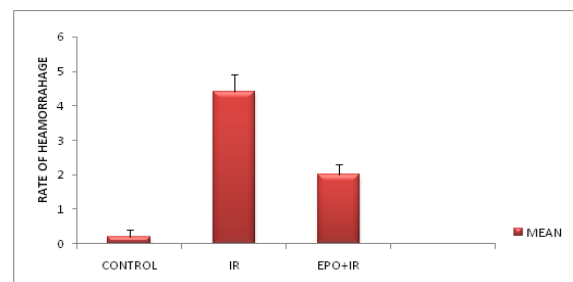


Fig. 2. Mean changes in hemorrhage of liver tissue in treatment and control group (n = 8). Data are shown as mean \pm SE.

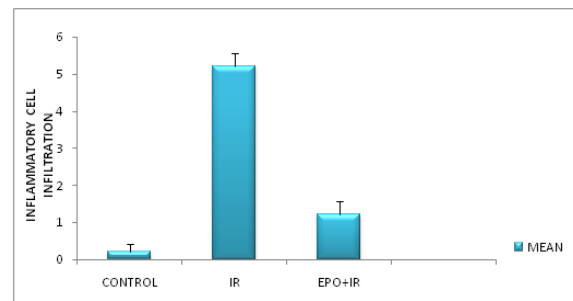


Fig. 3. Mean changes in inflammatory process in treatment and control group (n = 8). Data are shown as mean \pm SE.

The diverse effects of erythropoietin are the results of the induction of different routes signals. The

stimulation of EPO receptors causes diverse effects induction. For example, erythropoietin possess either cell protective effect and hematopoietic effect in various doses (Elmore, 2007). In mammals, the cells respond to ischemia by expression a series of proteins called EPO and vascular endothelial growth factor (VEGF). Of course, their expression is influenced by hypoxia inducible factor-1 (HIF-1) (Fadeel and Orrenius, 2005- Franklin *et al.*, 2006).

Erythropoietin is a glycoprotein with a molecular weight of 30.4 kD that its primary role is to regulate erythropoiesis. EPO is adjusted according to the rate of oxygen flow to tissues. Almost 90% of erythropoietin is produced in the kidney cells.

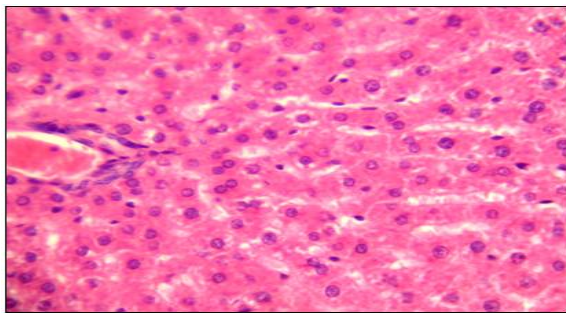


Fig. 4. Microscopic view of a rat liver from control group in which the normal tissue and central small veins as well as portal space are visible. Hematoxylin and eosin staining, magnification 40 ×.

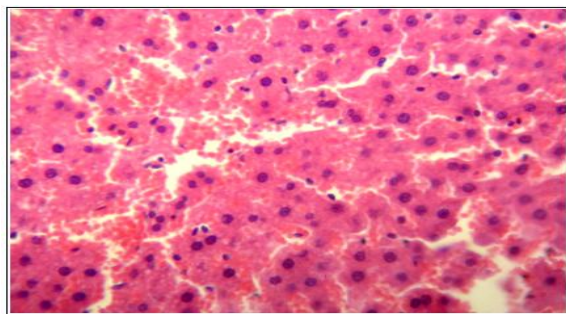


Fig. 5. Microscopic view of a rat liver from ischemia-reperfusion group, note the necrotic cells with picnotic core and hemorrhage. Hematoxylin and eosin staining, magnification 40 ×.

Decreased oxygen delivery to the liver results in increased stimulation of erythropoietin production by the kidneys and the stimulation of blood circulation (Han *et al.*, 2008).

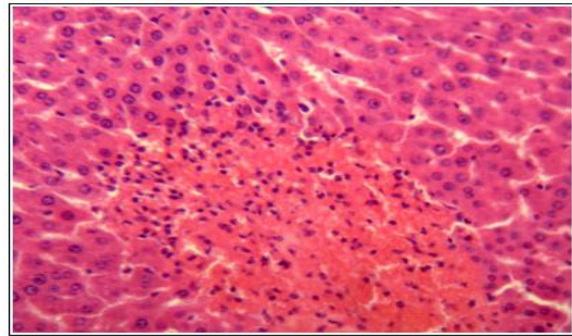


Fig. 6. Microscopic view of a rat liver from ischemia-reperfusion group, note the necrotic cells with picnotic core and severe hemorrhage along with abundant accumulation of kupffer cells. hepatoma cells are also visible in some parts of the tissue suggesting tissue damage. Hematoxylin and eosin staining, magnification 40 ×.

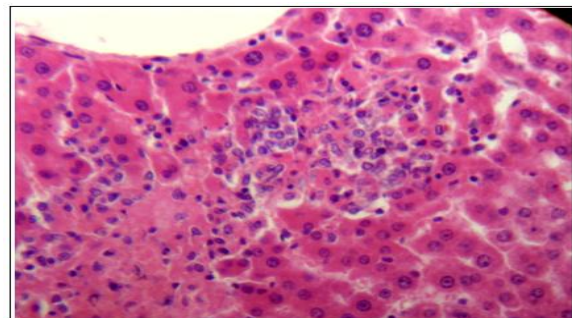


Fig. 7. Microscopic view of a rat liver from ischemia-reperfusion group in which a severe necrosis around central small veins of megalocyte cells along with abundant accumulation of inflammatory and kupffer cell are visible. Hematoxylin and eosin staining, magnification 40 ×

Many studies have shown that EPO can reduce negative effects of hypoxia, oxidative stress, hemorrhagic shock via reduced caspase activity and inhibition of apoptotic cell death in the liver. Erythropoietin has non-hemeopoietic effect on the liver cells especially on liver cells with its mitogenic role. Oxidative stress is a major cause of hepatic ischemia resultant injuries (Hetz, 2008). Erythropoietin is the major regulator of On the other hand, a theory can be raised that EPO has a direct effect on damaged sinusoids epithelial cells as a result of ischemia-reperfusion. The proliferation and differentiation of erythroid precursor cells with its anti-apoptotic effects. Erythropoietin gene expression

is under the control of hypoxia inducible factor-1 (HIF-1) which itself is controlled by HIF-1 α and HIF-1 β . HIF-1 controls the expression of several cytokines, such as vascular endothelial growth factor (VEGF), which is induced in response to ischemia and it also is involved in glucose metabolism. In the present study, the role of erythropoietin on ischemia-reperfusion-induced liver damage was investigated.

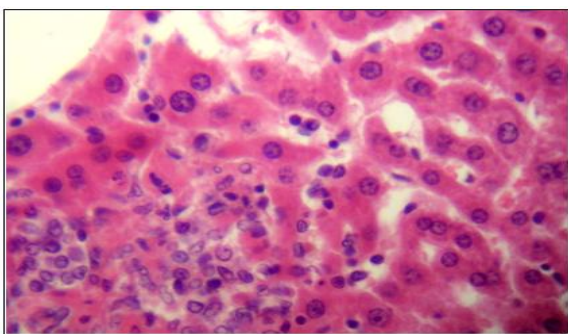


Fig. 8. Microscopic view of a rat liver from ischemia-reperfusion group in which a severe necrosis around central small veins along with abundant accumulation of Kupfer cells are visible. Hematoxylin and eosin staining, magnification 40 \times .

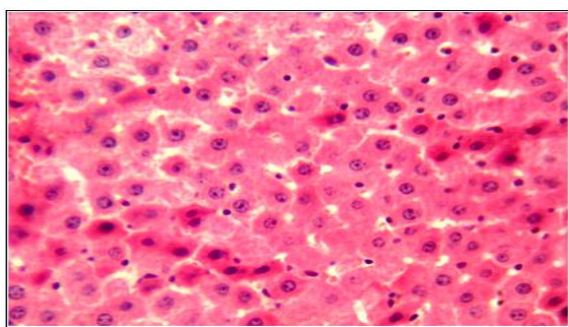


Fig. 9. Microscopic view of a rat liver from ischemia-reperfusion group in which a severe and sporadic necrosis, necrotic cells with a glassy appearance and picnotic nuclei are visible. Hematoxylin and eosin staining, magnification 20 \times .

In this study, it was observed that EPO can reduce liver damage as well as reduce inflammation induced by 30 min of ischemia and 24 hours of reperfusion. In this study, erythropoietin has been administered intraperitoneally at least one hour before ischemia. It was always a question that how erythropoietin can protect the cell; so, different mechanisms have been considered by many authors. It seems that one of the mechanisms is blood flow increase by EPO that

protects cells. It can be claimed that the EPO increases liver parenchymatous perfusion so exerts a protective effect. EPO exerts its protective effect on hepatic cells via direct inhibition of oxidative damages and then by its receptors (Hetz, 2008; Kurosaka *et al.*, 2003).

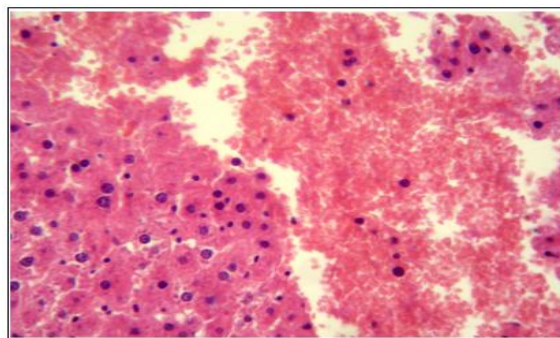


Fig. 10. Microscopic view of a rat liver from ischemia-reperfusion group that severe necrosis along with severe hemorrhages are visible. Hematoxylin and eosin staining, magnification 20 \times .

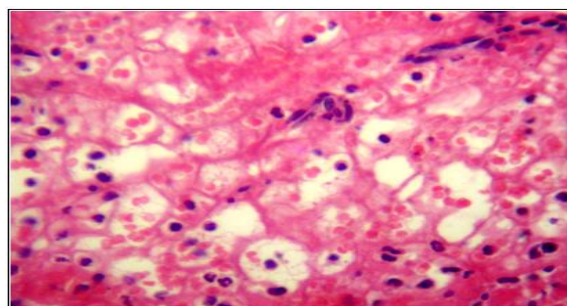


Fig. 11. Microscopic view of a rat liver from ischemia-reperfusion group that severe necrosis along with severe hemorrhages as well as neutrophil infiltration are visible. Hematoxylin and eosin staining, magnification 40 \times .

EPO activates PI3K and AKT phosphorylation by activating the Janus Kinase 2 (JAK2) in hepatic cells. By AKT activation the multipurpose anti-apoptotic effects such as BAD, BAX, caspase 9, GSK3 β phosphorylation, stability of mitochondrial membrane potential, and ATP synthesis began to appear. Therefore, EPO acts by binding to its receptors and protects proximal tubular cells via apoptosis inhibition. XJAP is the important mediator involved in liver protection that acts followed by EPO administration, since: 1) inhibit directly the activity of caspase 3, 7, 9, 2) acts by modification of death receptor, FAS. On the other hand, XJAP exerts its

anti-apoptotic effect directly by stimulation of P21CIP1 which ceases cell proliferation in G₂/S. EPO causes to reduce caspase3 activity and its inhibition by caspase inhibition via mitochondrial caspase 9 route and caspase8 activity inhibition. Increased production of TNF- α followed by ischemia-reperfusion and consequently the stimulation of nuclear factor β cause cell death induction and in this case EPO can inhibit nuclear factor β (Hochhauser *et al.*, 2008- Lamkanfi *et al.*, 2006).

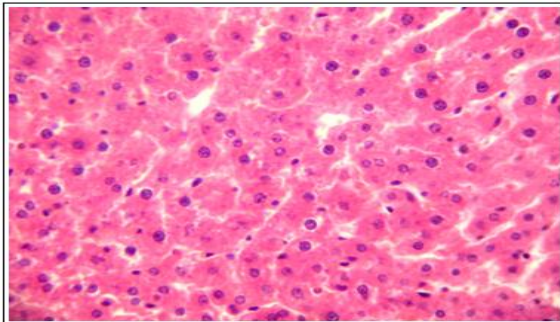


Fig. 12. Microscopic view of a rat liver from EPO recipient group without ischemia-reperfusion in which the liver has normal histologic structure are visible. Hematoxylin and eosin staining, magnification 20 \times .

A possibility for the protective function of EPO in ischemic liver can be resulted of improved hemodynamic function. It seems that EPO besides an anti-apoptotic effect has anti-inflammatory effects, too. The idea has been consolidated by the effect of EPO on experimental model of auto-immune encephalomyelitis.

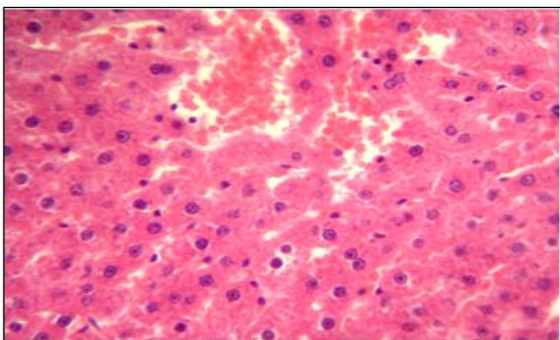


Fig. 13. Microscopic view of a rat liver from EPO recipient group with ischemia-reperfusion in which hemorrhage with mild damage compared with ischemia-reperfusion are visible. Hematoxylin and eosin staining, magnification 20 \times .

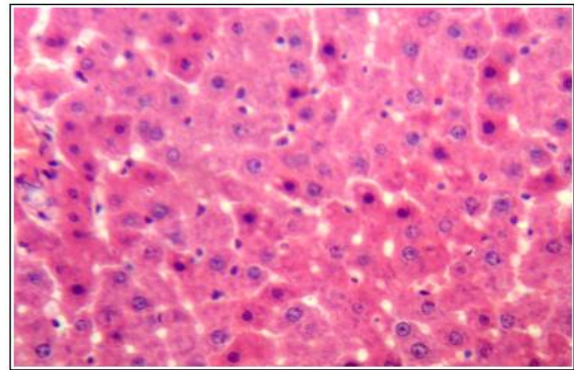


Fig. 14. Microscopic view of a rat liver from EPO receptor group with ischemia-reperfusion in which a mild damage of tissue and reduced inflammation compared with ischemia-reperfusion are visible. Hematoxylin and eosin staining, magnification 20 \times .

EPO causes vascular mitogenic and angiogenesis induction by endothelial sinusoidal cell stimulation that improves oxygen delivery to the tissues. EPO improves angiogenesis and is effective in lesions restoration. Also, it must be noted that EPO is the most important and the strongest stimulant of endothelial precursor cells and their egression from marrow. By existence of the precursors in blood, the power of damaged endothelium reconstruction is improved.

References

- Barr PJ, Tomei LD.** 1994. Apoptosis and Its Role in Human Disease. *Nature Biotechnology* **12**, 487-493.
<http://dx.doi.org/10.1038/nbt0594-487>
- Bramey T, Freitag P, Fandrey J, Rauen U, Pamp K, Erhard J, Frede S, de Groot H, Petrat F.** 2009. No Evidence for Protective Erythropoietin Alpha Signalling in Rat Hepatocytes. *BMC gastroenterology* **9**, 26.
<http://dx.doi.org/10.1186/1471-230X-9-26>
- Eipel C, Hübschmann U, Abshagen K, Wagner KF, Menger MD, Vollmar B.** 2012. Erythropoietin as Additive of Htk Preservation Solution in Cold Ischemia/Reperfusion Injury of Steatotic Livers. *Journal of Surgical Research* **173**, 171-179.
<http://dx.doi.org/10.1016/j.jss.2010.09.008>

Elmore S. 2007. Apoptosis: A Review of Programmed Cell Death. *Toxicologic pathology* **35**, 495-516.

<http://dx.doi.org/10.1080/01926230701320337>

Fadeel B, Orrenius S. 2005. Apoptosis: A Basic Biological Phenomenon with Wide- Ranging Implications in Human Disease. *Journal of internal medicine* **258**, 479-517.

<http://dx.doi.org/10.1111/j.1365-2796.2005.01570.x>

Franklin DJ, Brussaard CP, Berges JA. 2006. What Is the Role and Nature of Programmed Cell Death in Phytoplankton Ecology? *European Journal of Phycology* **41**, 1-14.

<http://dx.doi.org/10.1080/09670260500505433>

Han SI, Kim YS, Kim TH. 2008. Role of Apoptotic and Necrotic Cell Death under Physiologic Conditions. *BMB Rep* **41**, 1-10.

<http://dx.doi.org/10.5483/BMBRep.2008.41.1.001>

Hetz C. 2008. Editorial [Apoptosis, Necrosis and Autophagy: From Mechanisms to Biomedical Applications (Part-I) Guest Editor: Claudio Hetz]. *Current molecular medicine* **8**, 76-77.

<http://dx.doi.org/10.2174/156652408783769607>

Hochhauser E, Pappo O, Ribakovsky E, Ravid A, Kurtzwald E, Cheporko Y, Lelchuk S, Ben-Ari Z. 2008. Recombinant Human Erythropoietin Attenuates Hepatic Injury Induced by Ischemia/Reperfusion in an Isolated Mouse Liver Model. *Apoptosis* **13**, 77-86.

<http://dx.doi.org/10.1007/s10495-007-0155-8>

Joyeux-Faure M. 2007. Cellular Protection by Erythropoietin: New Therapeutic Implications? *Journal of Pharmacology and Experimental Therapeutics* **323**, 759-762.

<http://dx.doi.org/10.1124/jpet.107.127357>

Kurosaka K, Takahashi M, Watanabe N, Kobayashi Y. 2003. Silent Cleanup of Very Early Apoptotic Cells by Macrophages. *The Journal of Immunology* **171**, 4672-4679.

<http://dx.doi.org/10.4049/jimmunol.171.9.4672>

Lamkanfi M, Festjens N, Declercq W, Berghe TV, Vandenabeele P. 2006. Caspases in Cell Survival, Proliferation and Differentiation. *Cell Death & Differentiation* **14**, 44-55.

<http://dx.doi.org/10.1038/sj.cdd.4402047>